

Facial-Stapedial Synkinesis Following Acute Idiopathic Facial Palsy

Michael Hutz, MD; Margaret Aasen; John Leonetti, MD

ABSTRACT

Introduction: While most patients note a complete resolution of facial paralysis in Bell's Palsy, up to 30% will have persistent facial weakness and develop synkinesis. All branches of the facial nerve are at risk for developing synkinesis, but stapedial synkinesis has rarely been reported in the literature.

Case Presentation: A 45-year-old man presented with sudden onset, complete right facial paralysis. One-and-a-half years later, he had persistent facial weakness and synkinesis. He noted persistent right aural fullness and hearing loss. Audiometry demonstrated facial-stapedial synkinesis.

Discussion: The patient was diagnosed with stapedial synkinesis based on audiometric findings by comparing his hearing at rest and with sustained facial mimetic movement. A literature review revealed 21 reported cases of this disorder.

Conclusions: Facial-stapedial synkinesis is an underdiagnosed phenomenon for patients recovering from idiopathic facial palsy. Patients who develop facial synkinesis also may have a component of stapedial synkinesis and should be referred to an otolaryngologist if they complain of any otologic symptoms, such as unilateral hearing loss or tinnitus. Definitive management involves surgical transection of the stapedial tendon.

INTRODUCTION

Bell's Palsy, or idiopathic acute facial paralysis, is a common occurrence, with an annual incidence of 15 to 30 per 100,000 and a lifetime risk of 1 in 60.¹ While 70% of patients will have

• • •

Author Affiliations: Department of Otolaryngology – Head and Neck Surgery, Loyola University Medical Center, Maywood III (Hutz, Leonetti); Loyola University Chicago Stritch School of Medicine, Maywood III (Aasen).

Corresponding Author: Michael Hutz, MD, Loyola University Medical Center, Department of Otolaryngology – Head and Neck Surgery, 2160 S 1st Ave, Maywood IL 60153; phone 708.216.8523; email mikehutz@gmail.com; ORCID ID 0000-0003-2921-6967.

complete resolution of their unilateral facial paralysis, the remaining patients manifest persistent paralysis or develop synkinesis, which occurs when a voluntary muscle movement causes a simultaneous involuntary contraction of other muscles. The facial nerve is the 7th cranial nerve and is primarily affected in Bell's Palsy. It acts to control the muscles of facial expression and conveys taste sensation to the anterior two-thirds of the tongue.

Faulty facial nerve regeneration following Bell's Palsy commonly leads to abnormal muscle contractions of the eye, mouth, mid-face, and neck. For example, a voluntary smile may lead to the involuntary closure of the ipsilateral eye. However, other branches of the facial nerve may theoretically be involved with synkinesis

as well. The stapedial nerve is a branch of the facial nerve that innervates the stapedius muscle. The stapedial tendon attaches to the stapes bone, which is the third ossicle within the middle ear. Contraction of the stapedius muscle typically occurs in the presence of very loud noises entering the ear, causing a stabilization of the stapes bone and dampening of that sound.

Stapedial synkinesis following Bell's Palsy was first described in 1974 by Watanabe et al, and there have been few reported cases of this condition.² However, we believe that it may be much more prevalent than previously realized. We present a case of facial-stapedial synkinesis, objectively confirmed on audiometry, following incomplete recovery of Bell's Palsy.

CASE PRESENTATION

A 45-year-old man presented to an academic otolaryngology practice 5 weeks after acute-onset, complete right facial paralysis for which he was treated with a course of oral prednisone in an emergency department. Subsequent magnetic resonance imaging showed facial nerve inflammation in the perigeniculate region, consistent with Bell's Palsy. His paralysis had improved since the initial onset, but he was still judged to be a House-Brackmann III function with complete eye closure and some movement of the forehead and perioral region. Four weeks later, he complained of aural fullness and decreased hearing.

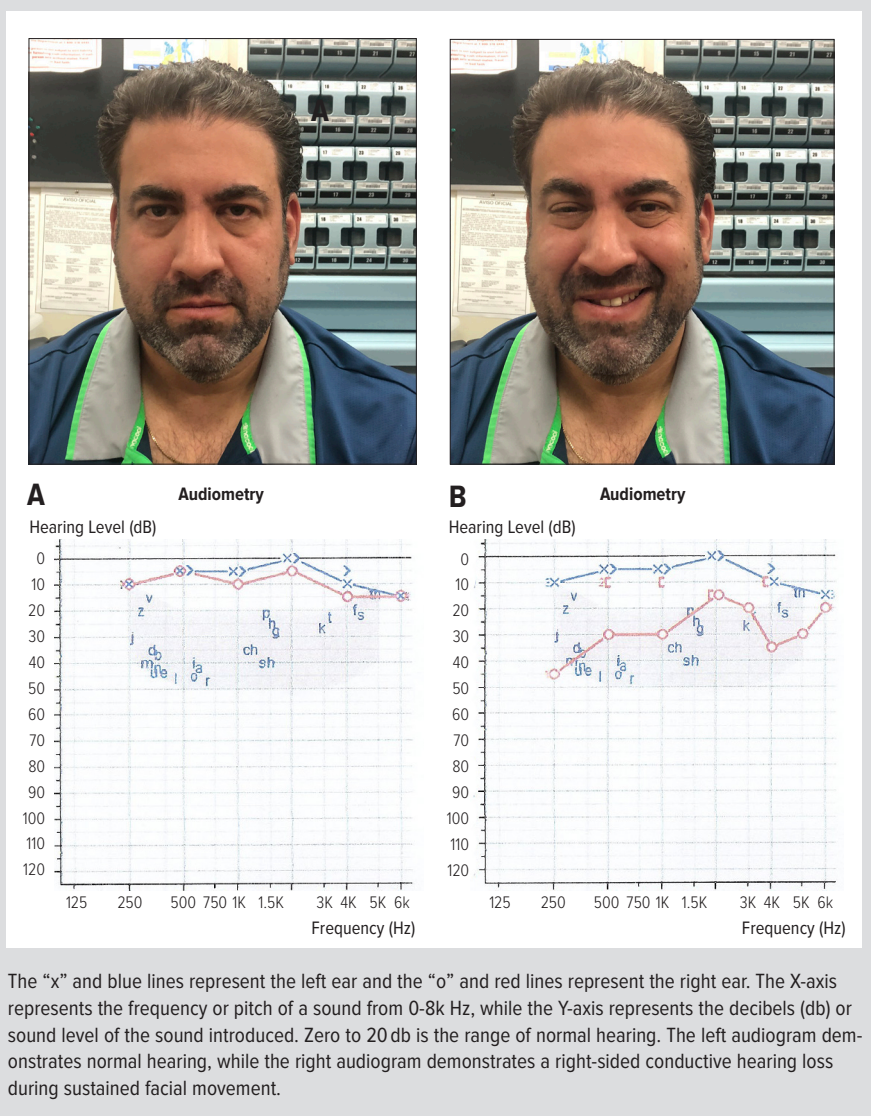
Four months after initial presentation at the clinic, the patient continued to note abnormal sounds and pressure in the right ear that occurred with smiling or eye closure. One year later, he displayed worsened right-sided synkinesis with significant involuntary eye closure with smiling. He complained of a persistent rumbling sensation in the right ear and muffled hearing associated with facial movement. An audiogram revealed normal hearing bilaterally (Figure A). A second audiogram performed during sustained facial movement demonstrated a 20 to 40 decibel conductive hearing loss in the right ear (Figure B). The patient was diagnosed with facial-stapedial synkinesis and was offered definitive surgical intervention with transection of the stapedial tendon. He declined surgical intervention and opted for observation.

DISCUSSION

Facial-stapedial synkinesis, also known as oculo-stapedial synkinesis, describes the aberrant, nonacoustic contraction of the stapedius muscle with voluntary facial movements. It has been reported in the literature in 21 cases following recovery from acute idiopathic facial palsy (Table).²⁻⁵ The ages of these patients ranged from 16 to 58, and the onset of hearing loss and/or tinnitus developed between 1 month and 1 year following the acute onset of facial paralysis.

Given the significant incidence of Bell's Palsy, facial-stapedial synkinesis is likely to be a very underreported phenomenon. The diagnosis can be difficult to obtain as patients may present with a

Figure. Audiometry performed at rest (A) and with sustained facial movement (B)



variety of vague symptoms such as tinnitus, hearing loss, or aural fullness. If these symptoms are related to voluntary facial movements in the presence of visible synkinesis of other facial muscles, a subjective diagnosis of facial-stapedial synkinesis can be made.

An objective diagnosis of facial-stapedial synkinesis was obtained in our case through the use of audiometry with the patient at rest and with sustained facial mimetic movement. If a patient presents with symptoms or signs consistent with facial-stapedial synkinesis, objective diagnosis may be obtained with audiometry or by evaluating middle ear compliance during sustained voluntary facial movement. If the diagnosis may be more definitively obtained, it precludes the need for exploratory surgery.

In the cases described in the literature, management involved surgical sectioning of the stapedial tendon via a transcanal approach, under both local and as general anesthesia. The benefit of a local anesthetic is that a diagnosis may be confirmed while

Table. Reported Cases of Facial-Stapedial Synkinesis Following Bell's Palsy

Patient No.	Age	Sex	Affected Side	Recovery	Symptom Onset	Treatment	Outcome	Author
1	19	F	L	Near complete	40 days	Stapedial tendon transection	Resolved	Watanabe et al ²
2	28	M	L	Incomplete	Several months	Stapedial tendon transection	Resolved	Watanabe et al ²
3	26	M	R	Incomplete	11 months	Stapedial tendon transection	Resolved	Watanabe et al ²
4	20	M	L	Incomplete	6 months	NR	NR	Yamamoto et al ³
5	16	M	R	Complete	NR	NR	NR	Yamamoto et al ³
6-18	NR	NR	NR	NR	NR	NR	NR	Yamamoto et al ³
19	58	F	L	Incomplete	2 months	Stapedial tendon transection	Resolved	Donne et al ⁴
20	56	M	R	Near complete	NR	Stapedial tendon transection	Resolved	Williams et al ⁵
21	45	M	R	Incomplete	2 months	N/A	N/A	Hutz et al

Abbreviations: F, female; M, male, NR, no response.

directly observing the stapes and stapedial tendon as the patient performs voluntary facial movements. There were no reported cases of hyperacusis postoperatively. Therefore, for patients who are highly symptomatic, transcanal sectioning of the stapedial tendon is a reasonable and definitive management option.

CONCLUSIONS

Facial-stapedial synkinesis is a possible long-term consequence of faulty neural regeneration in patients following acute idiopathic facial palsy. Patients who develop facial synkinesis who also complain of unilateral hearing loss, tinnitus, or aural fullness also may suffer from stapedial synkinesis. These patients should be referred to an otolaryngologist. Definitive management involves sectioning of the stapedial tendon.

Acknowledgements: Presented at the American Neurotology Society Meeting Facial Nerve Study Group Annual Meeting, Atlanta, Georgia, October 6, 2018.

Funding/Support: None declared.

Financial Disclosures: None declared.

REFERENCES

1. Tiemstra JD, Khatkhate N. Bell's palsy: diagnosis and management. *Am Fam Physician.* 2007;76(7):997-1002.
2. Watanabe I, Kumagami H, Tsuda Y. Tinnitus due to abnormal contraction of stapedial muscle. An abnormal phenomenon in the course of facial nerve paralysis and its audiological significance. *ORL J Otorhinolaryngol Relat Spec.* 1974;36(4):217-226. doi:10.1159/000275177
3. Yamamoto E, Nishimura H, Iwanaga M. Tinnitus and/or hearing loss elicited by facial mimetic movement. *Laryngoscope.* 1985;95(8):966-970. doi:10.1288/00005537-198508000-00016
4. Donne AJ, Homer JJ, Woodhead CJ. Oculostapedial synkinesis following Bell's palsy. *J Laryngol Otol.* 2000;114(2):135-136. doi:10.1258/0022215001904888
5. Williams T, Tunland B, Stobbs N, Watson G. Oculostapedial synkinesis following idiopathic facial palsy: something to listen out for. *J Laryngol Otol.* 2018;132(8):757-758. doi:10.1017/S0022215118001147