

# Achenbach Syndrome in Primary Care: A Case Report

Paula Aguirre-Bejarano, MD; Eduardo Tuta-Quintero, MD; Claudia Mora-Karam, MD; Sergio Quiroga-Segura, MD; Juan Pimentel, MD

## ABSTRACT

Paroxysmal hematoma of the fingers, or Achenbach syndrome, is a rare vascular disorder of benign course and unknown etiology. The clinical manifestations are sudden onset, paroxysmal spontaneous subcutaneous hematomas, and edema and pain in the fingers and hands. The clinical course is self-limited and does not leave permanent sequela. The diagnosis is clinical, and complementary studies are often unnecessary. We present the clinical case of a 69-year-old woman diagnosed with Achenbach syndrome in a primary care center in Colombia.

## INTRODUCTION

The German physician Walter Achenbach first described a rare condition that he called “paroxysmal hand hematoma” or “finger apoplexy” in 1958.<sup>1</sup> Achenbach syndrome or paroxysmal finger hematoma is a female-dominant disease of unknown etiology with a median age at presentation of 50 years.<sup>2</sup> The clinical manifestations are characterized by a paroxysmal, spontaneous subcutaneous hematoma on the palmar aspect of the proximal phalanges. Diagnosis is based on the clinical features, and there is no need for supplementary investigations.<sup>3</sup> The median time to resolution of symptoms is 1 week (2 to 14 days) without treatment.<sup>1,4</sup>

Although Achenbach syndrome is a benign, self-limited dis-

• • •

**Author Affiliations:** Department of Medicine, Hospital San Rafael de Pacho, Pacho, Colombia (Aguirre-Bejarano, Quiroga-Segura); Department of Internal Medicine, University of La Sabana, Chía, Colombia (Tuta-Quintero, Mora-Karam); Department of Family Medicine and Public Health, University of La Sabana, Chía, Colombia (Pimentel).

**Corresponding Author:** Eduardo Tuta Quintero, MD, Facultad de Medicina Edificio H Kilómetro 7 autopista norte. Campus Universitario puente del común, Chía, Colombia; email [Eduardotuqu@unisabana.edu.co](mailto:Eduardotuqu@unisabana.edu.co); phone +57 3204954596; ORCID ID 0000-0002-7243-2238

ease, primary care physicians are not usually trained to recognize and manage it. In this paper, we describe a case of Achenbach syndrome in a 69-year-old woman who presented to the emergency department with swelling, hematoma, and paresthesia in the third finger of the right hand. We aim to provide evidence to improve the diagnosis and management of this disease in primary care settings.

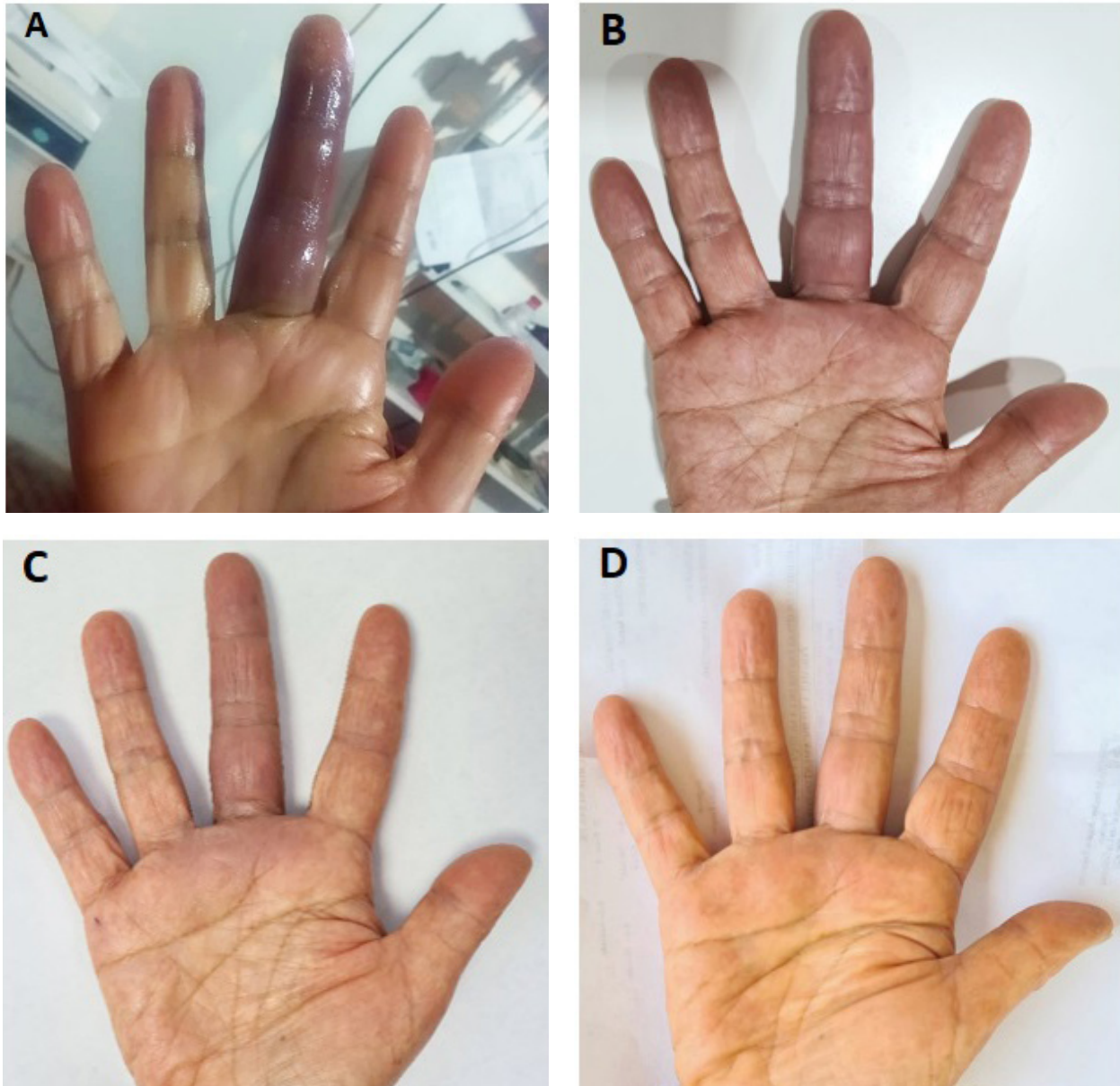
## CASE REPORT

A 69-year-old woman presented to the emergency department with an 8-hour history of a sudden inflammation of the third finger of the right hand, associated with mild pain, intense change of color, and paresthesia. She reported no history of causative triggers, such as preceding trauma, cold exposure, stress, or medication; however, she did report a similar episode 7 months prior, which was self-limited after 5 days, without requiring medical management or investigations. Additionally, she reported dyslipidemia on treatment with atorvastatin 20 mg per day. She had a negative toxic-allergic history and did not mention any personal or family history of thrombosis.

The patient had a tachycardia of 105 beats per minute and other vital signs were within physiological limits. Clinical examination revealed edema and change in skin color in the third finger of her right hand, predominantly in the palmar region of the proximal phalanges. On palpation, the area was not painful and had a normal capillary filling and no distal coldness. The brachial, radial, and ulnar artery pulses were palpable and symmetric, with preserved mobility of hands (Figure 1A).

Laboratory results (hemoglobin, leukocytes, hematocrit, platelets) were normal, and a diagnosis of Achenbach syndrome was made. Anti-inflammatory management and physical means were indicated. She had a favorable clinical course, with a total resolu-

**Figure.** Features of Achenbach's Syndrome



A. Day 0: Edema and discoloration of the third finger of the right hand, respecting the distal end; B. Day 1: Decrease in edema, evident discoloration; C. Day 2: Resolution of edema, a slight color change; D. Day 3: Full resolution.

tion of the symptoms on the third day, which is evidenced in Figure 1. We did not request doppler ultrasonography, angiography, or any additional investigation. The patient signed informed consent to be able to use data from the medical history and photographs.

## DISCUSSION

Achenbach syndrome is a rare and self-limited vascular condition of unknown etiology that causes paroxysmal bruising of the fingers. In actuality, it is a neglected disease in primary care, mainly

because it does not cause mortality or morbidity and there is low prevalence worldwide.<sup>4,5</sup> We report this case of Achenbach syndrome to increase awareness and provide information regarding the diagnosis, clinical course, and outcome of the disease. The diagnosis is essentially based on history and clinical examination; there is no need for additional investigations, especially if they are invasive.<sup>1,4,5</sup> Primary care physicians can use this information to optimize the clinical approach to patients with Achenbach syndrome.

Clinical manifestations of Achenbach syndrome are charac-

terized by a paroxysmal, spontaneous subcutaneous hematoma on the on the palmar aspect of the proximal phalanges proximal, middle, and distal phalanges (primarily in the middle and ring fingers), episodic pain (58%), and swelling (58%) without a history of prior coagulopathy or trauma.<sup>3,4</sup> Clinical examination should rule out absence of pulse, pallor, pruritus, ulceration, and necrosis that suggests acute limb ischemia, acrocyanosis, and chilblains. It is important to rule out clinical presentations that may manifest with cold and blue-to-white colored fingers, such as Raynaud's phenomenon.<sup>2,6</sup> In this case, clinical manifestations included a paroxysmal spontaneous subcutaneous hematoma on the palmar aspect of the proximal phalanges in 1 or more fingers and episodic pain. The clinical examination revealed pulses present without skin lesions.

Achenbach syndrome is a condition of unknown etiology.<sup>7,8</sup> However, the pathophysiology may be related to the presence of capillary fragility with extravasation of red blood cells, hyperkeratosis, and generalized ectatic capillaries within the dermis.<sup>7-9</sup> The F3 and F2 genes have been associated with capillary fragility and Achenbach syndrome; these genes code for the coagulation factor II and III, respectively.<sup>9</sup>

In some cases, bleeding can occur due to venous rather than arterial hemorrhage, and infiltration and compression affect the extravasated blood.<sup>5</sup> Paradoxically, the lesions disappear without going through the typical stages of ecchymosis reabsorption, and the hand always has a normal temperature.<sup>7</sup> The signs and symptoms are alarming to most patients, who may be referred to vascular surgeons and exposed to unnecessary diagnostic images, such as doppler and angiography, which should be used to rule out stenosis and thrombosis. Skin biopsy can confirm or rule out vasculitis and may demonstrate nonspecific signs such as minor bleeding and inflammation.<sup>7,10</sup> In this case, we did not request image-based investigations or biopsies due to unavailability at the health center.

The painful discoloration resolves on its own, and treatment consists of reassuring the patient to avoid increased pain due to anxiety.<sup>5,11</sup> In our case, no specific treatment was proposed initially due to the high suspicion of Achenbach syndrome on history and clinical examination. Without any treatment, the median time to resolution of signs and symptoms is 1 week (2 to 14 days).<sup>2</sup> Recurrent episodes may occur in months or years without any apparent sequelae.<sup>3,7</sup>

## CONCLUSIONS

The acute clinical presentation of Achenbach syndrome often generates concern among primary care physicians due to the fear of a pathology that could permanently damage the fingers. It is important to recognize this condition to reassure the patient and avoid unnecessary investigations. Diagnosis in this case was based on clinical findings as investigations are completely normal. This report will assist with rapid diagnosis and

proper management of Achenbach syndrome in primary care, avoiding unnecessary referrals and invasive exams. The prognosis of Achenbach syndrome did not leave apparent sequelae in the patient.

**Financial Disclosures:** None declared.

**Funding/Support:** None declared.

---

## REFERENCES

1. Achenbach W. Das paroxysmale handhämatom [Paroxysmal hematoma of the hand]. *Medizinische*. 1958;52(27):2138-2140.
2. Kordzadeh A, Caine PL, Jonas A, Rhodes KM, Panayiotopolous YP. Is Achenbach's syndrome a surgical emergency? A systematic review. *Eur J Trauma Emerg Surg*. 2016;42(4):439-443. doi:10.1007/s00068-015-0610-0
3. Godoy A, Tabares AH. Achenbach syndrome (paroxysmal finger hematoma). *Vasc Med*. 2019;24(4):361-366. doi:10.1177/1358863X19849627
4. Yie K. Achenbach syndrome: a benign painful blue finger with tip sparing. *Vasc Specialist Int*. 2019;35(4):251-253. doi:10.5758/vsi.2019.35.4.251
5. Ada F, Kasimzade F. Analysis of 24 patients with Achenbach's syndrome. *World J Clin Cases*. 2019;7(10):1103-1110. doi:10.12998/wjcc.v7.i10.1103
6. Jiménez PR, Ocampo MI, Castañeda-Cardona C, Rosselli D. Síndrome de Achenbach: Presentación de un caso y revisión sistemática de la literatura [Achenbach's syndrome: case report and systematic review of the literature]. *Rev Colomb Reumatol*. 2017;24(4):230-236. doi: 10.1016/j.rcreu.2017.06.004
7. Matellanes-Palacios M, Sabater-Abad J. Visual dermatology: Achenbach's syndrome (paroxysmal finger hematoma). *J Cutan Med Surg*. 2021;25(2):206. doi:10.1177/1203475420929020
8. Harnarayan P, Ramdass MJ, Islam S, Naraynsingh V. Achenbach's syndrome revisited: the paroxysmal finger hematoma may have a genetic link. *Vasc Health Risk Manag*. 2021;17:809-816. doi:10.2147/VHRM.S342847
9. Stelzer G, Rosen N, Plaschkes I, et al. The GeneCards suite: from gene data mining to disease genome sequence analyses. *Curr Protoc Bioinformatics*. 2016;54:1.30.1-1.30.33. doi:10.1002/cpbi.5
10. Sridharan M, Ali U, Hook CC, Nichols WL, Pruthi RK. The Mayo Clinic experience with psychogenic purpura (Gardner-Diamond syndrome). *Am J Med Sci*. 2019;357(5):411-420. doi:10.1016/j.amjms.2019.02.002
11. Gomes JF, Mendes J, Donaire D, Ferreira M. Achenbach's syndrome. *BMJ Case Rep*. 2020;13(9):e238156. doi:10.1136/bcr-2020-238156