

Ocular Findings Aid in Diagnosis of West Nile Virus

Brandon K. Winward, MD; Justin L. Gottlieb, MD; Jonathan S. Chang, MD; E. Luke Bradbury, MD; Nenita Maganti, MD; Chintan Pathak, MD; Benjamin J. Fowler, MD, PhD

ABSTRACT

Introduction: West Nile virus disease, which is endemic to the United States, is a rarely reported systemic infection that can be difficult to diagnose. Chorioretinitis is an uncommon manifestation of West Nile virus but has pathognomonic ocular findings that can aid in diagnosis.

Case Presentation: A 66-year-old man presented with acute onset fever, chills, and dyspnea. He underwent an extensive but nondiagnostic workup during hospitalization. New visual complaints prompted ophthalmology consultation. Funduscopic examination showed macular hemorrhages and midperipheral chorioretinal lesions. Fluorescein angiography revealed target-like lesions in a radial distribution, which is pathognomonic for West Nile virus chorioretinitis. Serology confirmed the diagnosis of West Nile virus disease. Systemic and ocular symptoms improved with supportive care.

Discussion: West Nile virus disease has many nonspecific manifestations. History of recent mosquito exposure is not always readily elicited. In patients with visual symptoms, eye examination can help in its diagnosis.

Conclusions: West Nile virus should be considered in patients with acute febrile or neurological illness during mosquito season.

INTRODUCTION

West Nile virus (WNV), originally isolated in 1937 in Uganda, is a zoonotic pathogen within the *Flaviviridae* family that is transmitted to humans from infected wild birds via mosquito vec-

• • •

Author Affiliations: Maine Medical Center, Portland, Maine (Winward); Department of Ophthalmology and Visual Sciences, University of Wisconsin School of Medicine and Public Health (UWSMPH), Madison, Wis (Gottlieb, Chang, Maganti, Pathak, Fowler); Department of Neurology, UWSMPH, Madison, Wis (Bradbury).

Corresponding Author: Benjamin J. Fowler, MD, PhD, University of Wisconsin School of Medicine and Public Health, Department of Ophthalmology and Visual Sciences, 2828 Marshal Ct, Suite 200, Madison, WI 52705; phone 608.263.7171; email Fowler7@wisc.edu; ORCID ID 0000-0001-8995-4131

tors.¹⁻³ Since WNV first appeared in the United States in 1999, the Centers for Disease Control and Prevention (CDC) has documented approximately 55,000 human cases throughout all 50 states.³ WNV is considered endemic to the United States.^{2,3} While periodic outbreaks can occur, human incidence is low in many areas. In Wisconsin, from 2016 through 2020, an average of only 21 human cases were reported each year.⁴

Approximately 80% of persons infected with WNV are asymptomatic.³ Fever, headache, weakness, myalgia, and gastrointestinal upset are common though nonspecific symptoms.^{2,3,5} The incubation period for WNV disease can be up to 14 days in immunocompetent patients and longer in immunocompromised hosts,³ making the diagnosis difficult when a

history of recent vector exposure is not readily available. Severe headache, neck stiffness, altered mental status, convulsions, paralysis, and vision loss may indicate neuroinvasive disease.³ Chorioretinitis is the most common manifestation of ocular WNV infection and has been found in over 85% of cases with ocular involvement. The chorioretinitis is pathognomonic and evident on funduscopic examination and ancillary ocular imaging, particularly fluorescein angiography.^{2,6-10}

We highlight a case of WNV disease in Wisconsin that presented with nonspecific symptoms. A history of mosquito exposure was not elicited initially. The patient underwent an extensive laboratory and imaging workup. Diagnosis was delayed until symptoms of chorioretinitis developed and prompted ophthalmic investigation, including fluorescein angiography. Understanding the risk factors, manifestations, and seasonal presence of WNV

within the region can lead to more timely and cost-efficient diagnosis.

CASE PRESENTATION

A 69-year-old man with past medical history of hypertension, cerebral vascular accident, dysphagia, urinary incontinence, major depressive disorder, and lumbar stenosis presented to the emergency department (ED) in September, 2021, with 1 day of progressive fever, chills, and dyspnea. Emergency medical services were called as the chills progressed to rigors. In the ED, he was febrile (103.1°F), tachycardic (120 beats/min), and hypoxemic (requiring 2L of supplemental oxygen via nasal cannula to maintain normal oxygen saturation). He was consistently normotensive. Basic metabolic panel, complete blood cell count, and urinalysis were unremarkable. Influenza and COVID-19 assays were negative. Chest radiograph showed opacities in the right lower lobe. Intravenous ceftriaxone and azithromycin were started, and the patient was admitted for presumed community-acquired pneumonia.

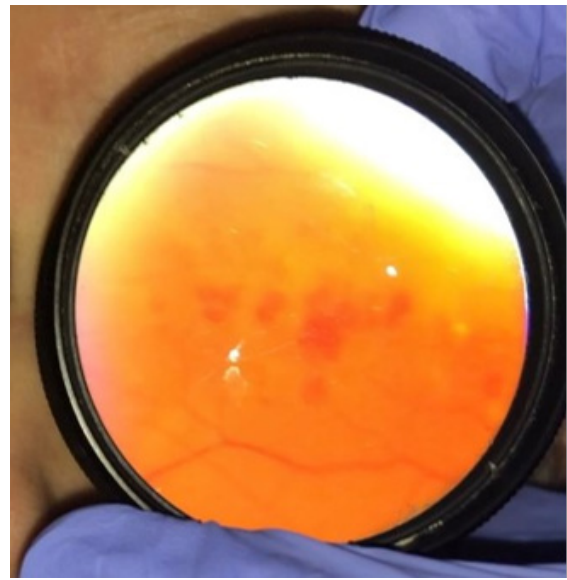
The patient received acetaminophen for intermittent fevers. His hypoxemia and fever slowly improved. Blood cultures drawn earlier in the ED resulted negative. The antibiotic regimen was transitioned to oral amoxicillin/clavulanate. He was discharged after hospital day 3 following a 24-hour period without fever or supplemental oxygen requirement.

The patient returned to the ED 3 days later with recurrent fever, chills, dyspnea, frontal headache, mild abdominal pain, and diarrhea. He confirmed adherence to his outpatient antibiotic regimen. He was febrile (102.7°F) and hypertensive (174/92 mm Hg) upon arrival and soon became hypoxemic, requiring 1 liter of supplemental oxygen via nasal cannula. His pulse was 90 beats per minute. Intravenous isotonic fluids, vancomycin, and cefepime were administered. He was admitted to the hospital under the working diagnosis of acute hypoxic respiratory failure due to community-acquired pneumonia, presumably refractory to outpatient antibiotics.

Complete blood cell count with differential showed a white blood cell count of 11,700 cells/microliter with 81% neutrophils. Peripheral blood smear showed 20% to 40% band cells. Additional laboratory workup, including comprehensive metabolic panel, urinalysis, bacterial and fungal blood cultures, cardiac troponins, erythrocyte sedimentation rate, procalcitonin, thyroid stimulating hormone, respiratory viral panel, *Legionella* urine antigen, *Streptococcus pneumoniae* urine antigen, and *Bordetella* species and common allergens, was unremarkable. Repeat chest radiograph showed largely unchanged opacities of the right lower lung fields. Computed tomography (CT) of the abdomen and pelvis was normal.

During admission, persistent headache and language fluency difficulties were noted. Neurological examination and CT of the head were normal. The neurology consult service recommended

Figure 1. Funduscopy



Retinal hemorrhages in the macula of the left eye visualized through a 20-diopter handheld lens at the patient bedside.

magnetic resonance imaging and angiography of the head and neck, which likewise showed no abnormalities. Headache and speech difficulties were consequently attributed to recrudescence of prior ischemic medullary stroke in the context of acute illness. The patient did not undergo a lumbar puncture.

On the 10th day of hospitalization, the ophthalmology service was consulted for new onset blurry vision and floaters in the patient's left eye. Pupils were equal, round, and reactive, without afferent pupillary defect. Best-corrected visual acuity (BCVA) was 20/30 and 20/70 in the right and left eye, respectively. Intraocular pressure was within normal limits in both eyes. Slit lamp biomicroscopy revealed early nuclear sclerotic cataracts in both eyes and mild vitreous haze in the left eye only. Dilated fundus exam of the right eye at presentation was normal; the left eye had retinal hemorrhages in the macula (Figure 1) and peripheral round chorioretinal lesions.

The patient's respiratory status improved, and he was discharged to a skilled nursing facility on the 14th day of hospitalization with same-day outpatient ophthalmology follow-up and multimodal ophthalmic imaging. Optical coherence tomography showed a few foci of outer retinal disruption in the macula of the left eye (Figure 2). Fundus photography and autofluorescence imaging revealed resolving macular hemorrhages and numerous round chorioretinal lesions (Figure 3A-B). Fluorescein angiography of the left eye highlighted many circular lesions with target-like rings of hyperfluorescence in a radial distribution (Figure 3C), which is pathognomonic for WNV chorioretinitis. Additional history revealed that the patient was

an avid photographer and frequently exposed to mosquitos in forested areas at dusk. He was started on a 3-week taper of ophthalmic prednisolone acetate in the left eye, and confirmatory serum studies were ordered. The index value for WNV-specific immunoglobulin G and M resulted 2.81 (normal <1.29) and 5.25 (normal <0.89), respectively. Supportive care was recommended for his systemic manifestations of WNV disease.

Six weeks later, the patient's systemic symptoms had resolved. BCVA improved to his baseline (20/30). The vitreous haze and macular hemorrhages resolved. Chorioretinal scarring was appreciated in areas of prior macular hemorrhage, and peripheral chorioretinal lesions had significantly faded. At 4-month follow-up, his ocular condition was stable.

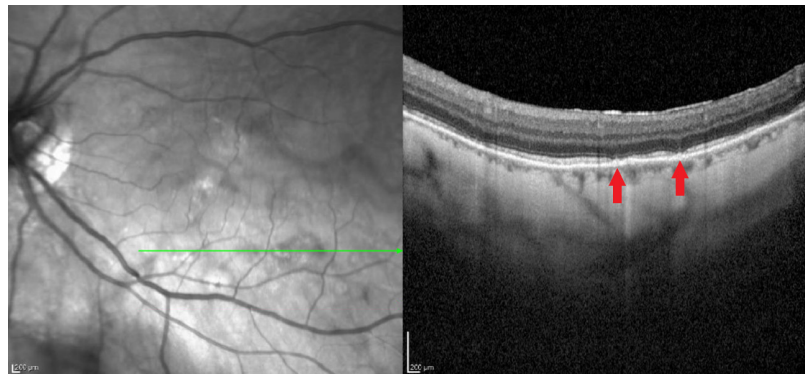
DISCUSSION

WNV diagnoses occur in areas of increased mosquito activity. In Wisconsin, WNV cases typically occur between June and October, with a peak in cases in August.⁴ WNV is the most common epidemic viral encephalitis in the United States;¹¹ clinicians should be aware of WNV disease, especially given the at-risk aging population and increased numbers of immunocompromised individuals in the United States. Moreover, the seasonal duration and burden of WNV is predicted to increase with rising global temperatures.¹² Acute WNV disease has a wide range of nonspecific manifestations;^{1,3,5,6,13} it can be difficult to diagnose, and patients may undergo extensive workup before WNV is considered.² History of recent mosquito exposure is not always available and, as in our case, might be gathered only after a diagnosis is made from objective findings.^{2,14}

Ocular symptoms are uncommon with WNV infection.^{2,6,7,9,10,13,15,16} Risk factors for ocular involvement include advanced age, immunosuppression, male sex, and diabetes.^{2,9} Ocular involvement of WNV may be asymptomatic or present with symptoms of decreased vision, floaters, photophobia, retrobulbar pain, or diplopia.^{2,6,7,9,10,13,16} Ocular manifestations of WNV include chorioretinitis, vitritis, retinal vasculitis, optic neuritis, and nystagmus.^{7,9} Table 1 summarizes a literature review of the reported ocular manifestations of WNV disease; chorioretinitis is the most common.^{2,9} In a cohort study of 111 patients with a history of WNV infection, 24% of patients had chorioretinal scars; if the patient had encephalitis, the prevalence of chorioretinal lesions was 49%.¹⁵

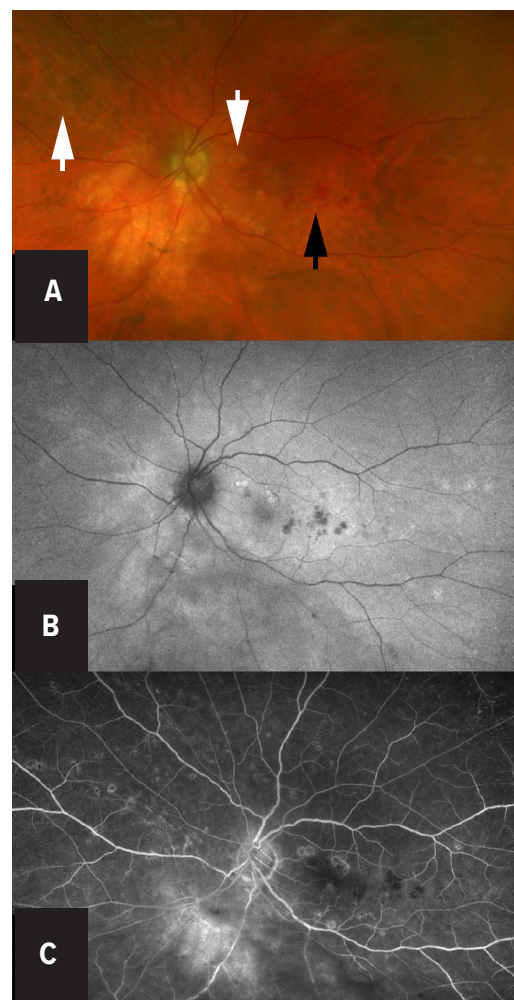
Chorioretinal lesions in acute WNV chorioretinitis are classically described as deep, round, cream-colored lesions.^{2,6,8-10} Fluorescein angiography usually shows pathognomonic "target-

Figure 2. Optical Coherence Tomography



Outer retinal disruption (red arrows) in the macula of the **left** eye.

Figure 3. Multimodal Fundus Imaging.



A. Fundus photograph of the left eye showing macular hemorrhages (black arrow) and scattered chorioretinal lesions (white arrows). B. Fundus autofluorescence of the left eye showing circular hyper-autofluorescent chorioretinal lesions. C. Fluorescein angiography of the left eye showing numerous target-like lesions with hyperfluorescent rings, radiating in a curvilinear pattern from the optic disc and throughout the fundus.

Table. Reported Ocular Manifestations of West Nile Virus Disease

Reference/Description	Reported Ocular Manifestation of West Nile Virus Disease							
	Sample Size	Multifocal Linear Chorioretinal Lesions	Vitritis (%)	Optic Disc Edema or Pallor (%)	Intraretinal Hemorrhages (%) ^a	Retinal Vasculitis (%)	Retinal Occlusive Vasculitis (%)	Misc (%)
Cross-sectional study of patients w history of WNV infection who underwent dilated fundus exam ¹⁵	111 patients	27 (24%)	N/A	N/A	N/A	N/A	N/A	
Clinic patients w/ocular inflammation and fever who tested positive for WNV ^{17 b}	51 eyes (37 patients)	7 eyes (14%)	37 eyes (73%)	7 eyes (14%)	22 eyes (43%)	Arteritis: 18 eyes (35%) Phlebitis: 15 eyes (29%)	8 eyes (16%)	
Patients hospitalized w/ WNV disease and ocular symptoms ^{18 b}	27 patients	0	0	11 (41%)	N/A	9 (33%)	2 (7%)	Peripapillary retinitis: 6 patients (22%)
Patients w/ WNV disease and neurological symptoms ¹⁹	29 patients	23 (79%)	23 (79%)	2 (7%)	21 (72%)	9 (31%)	N/A	Sixth nerve palsy: 1 patient, Nystagmus: 1 patient
Retrospective chart review of patients w/ ocular WNV ⁷	14 eyes (7 patients)	12 eyes (86%)	6 eyes (43%)	6 eyes (43%)	7 eyes (50%)	4 eyes (29%)	2 eyes (14%)	Sixth nerve palsy: 1 patient
Case series of patients w/ WNV chorioretinitis ²	3 patients	3 (100%)	3 (100%)	0	1 (33%)	0	0	

Abbreviation: N/A, not available; WNV, West Nile virus.

^aSome of the intraretinal hemorrhages may represent diabetic retinopathy.

^bThere may be some shared patients between these studies, which overlap in time at the same eye institute.

Data were obtained from a literature review of ocular manifestations of patients with serology/polymerase chain reaction-confirmed West Nile virus disease. Only case series with 3 or more patients were included. Search criteria included multiple PubMed searches using the keywords “West Nile virus,” “ocular,” “eye,” “ocular manifestation,” “WNV,” and “chorioretinitis.” If both eyes were affected, ocular manifestations are reported as positive if either eye had the manifestation. In some studies, only the number of eyes was available, which is noted above.

like” lesions (central hypofluorescence with a hyperfluorescent rim) radiating from the optic disc in a curvilinear fashion.^{2,6,8,9} It is thought that the curvilinear distribution of retinal lesions is related to the contiguous spread of virus from the central nervous system to the retina along nerve fiber layers, although there also might be hematogenous spread through the choroidal circulation.² Fundus autofluorescence and indocyanine green angiography – additional ancillary tests commonly ordered in the evaluation of chorioretinitis – also highlight this characteristic finding and help differentiate WNV from other forms of chorioretinitis.^{8,9} Optical coherence tomography may reveal multifocal disruption of the outer retina.^{2,8} Our patient manifested these classic ocular findings (Figures 1-3).

When systemic manifestations are also present, a laboratory diagnosis of WNV disease is often made prior to the diagnosis of WNV chorioretinitis.^{2,6,8-10,14} In one such case when serologies for WNV were positive but there was insufficient volume of cerebrospinal fluid (CSF) for WNV testing, the presence of chorioretinitis was interpreted as an indication of neuroinvasive disease.⁶ However, in our case and a case described by Learned et al in 2014,² the diagnosis of WNV infection was primarily driven by ocular findings. Still, serum antibody testing (and CSF

analysis when there is suspicion for neuroinvasive disease) is the recommended initial procedure when considering a diagnosis of WNV disease. In our patient, chorioretinitis and mental status changes were suggestive of central nervous system involvement, although he did not have more worrisome signs of neuroinvasive disease, such as ventral spinal root involvement, which can cause flaccid paralysis. It is possible that the lack of serious neurologic symptoms and prior diagnosis of community-acquired pneumonia before the onset of ocular symptoms delayed a workup for WNV, which is often a component of encephalitis viral panels. Nevertheless, regardless of severity of WNV infection, treatment is largely supportive.

WNV infection is reportable to local and national public health services in the United States;³ in Wisconsin, these services are the Wisconsin Department of Health Services and the CDC. Various medications and vaccines have been evaluated in clinical studies for use in preventing or treating WNV, but none have shown substantial clinical benefit in humans.^{3,9} Supportive therapy is the only recommended treatment for WNV disease.^{3,9} Community-level mosquito control programs and personal protective wear are effective preventive measures.³

Ocular disease typically is self-limited, but topical steroids

and cycloplegics can be given for inflammation and pain.^{2,9} We prescribed a short course of tapered topical steroids in this case. Persistent visual loss, though rare, may occur in instances of retinal scarring, choroidal neovascularization, nonclearing vitreous hemorrhage, and macular edema.^{7,9,16}

CONCLUSIONS

Acute WNV disease can be difficult to diagnose but should be considered, in addition to other arboviruses, in patients with an acute febrile or neurological illness. Common symptoms include headache, myalgia, arthralgia, gastrointestinal distress, and transient maculopapular rash.³ Eliciting a history of mosquito exposure can be helpful in making the diagnosis, keeping in mind the incubation period is typically 2 to 6 days but can be longer.³ Laboratory serology testing is recommended when there is suspicion for WNV disease. Ophthalmology consultation may be useful in the diagnosis and reporting of WNV disease in patients with ocular symptoms

Funding/Support: This work was supported in part by an unrestricted grant from Research to Prevent Blindness, Inc. to the UW-Madison Department of Ophthalmology and Visual Sciences. Dr Fowler received a research fellowship from the Heed Ophthalmic Foundation.

Financial Disclosures: None declared.

Acknowledgments: The authors wish to thank Susan Paskewitz, PhD, from the Department of Entomology, University of Wisconsin-Madison, for her review of the manuscript.

REFERENCES

1. Craven RB, Roehrig JT. West Nile virus. *JAMA*. 2001;286(6):651-653. doi:10.1001/jama.286.6.651
2. Learned D, Nudleman E, Robinson J, et al. Multimodal imaging of west nile virus chorioretinitis. *Retina*. 2014;34(11):2269-2274. doi:10.1097/IAE.0000000000000213
3. Centers for Disease Control and Prevention. West Nile virus. Updated March 29, 2023. Accessed June 29, 2022. <https://www.cdc.gov/westnile/index.html>
4. Wisconsin Department of Health Services. West Nile virus: data. Updated March 6, 2023. Accessed July 17, 2022. <https://www.dhs.wisconsin.gov/mosquito/wnv-data.htm>
5. Petersen LR, Marfin AA. West Nile virus: a primer for the clinician. *Ann Intern Med*. 2002;137(3):173-179. doi:10.7326/0003-4819-137-3-200208060-00009
6. Arjmand P, Mandelcorn ED. Chorioretinitis: a diagnostic clue to West Nile neuroinvasive disease. *IDCases*. 2021;25:e01167. doi:10.1016/j.idcr.2021.e01167
7. Chan CK, Limstrom SA, Tarasewicz DG, Lin SG. Ocular features of West Nile virus infection in North America: a study of 14 eyes. *Ophthalmology*. 2006;113(9):1539-1546. doi:10.1016/j.ophtha.2006.04.021
8. Golshani C, Venkat A, Srivastava SK. Multimodal imaging findings in acute West Nile virus chorioretinitis. *Retin Cases Brief Rep*. 2023;17(3):309-314. doi:10.1097/ICB.0000000000001162
9. Rousseau A, Haigh O, Ksiao I, Khairallah M, Labetoulle M. Ocular Manifestations of West Nile Virus. *Vaccines (Basel)*. 2020;8(4):641. doi:10.3390/vaccines8040641
10. Shaikh S, Trese MT. West Nile virus chorioretinitis. *Br J Ophthalmol*. 2004;88(12):1599-1600. doi:10.1136/bjo.2004.049460
11. Venkatesan A. Encephalitis and brain abscess. *Continuum (Minneapolis)*. 2021;27(4):855-886. doi:10.1212/CON.0000000000001006
12. Ogden NH, Gachon P. Climate change and infectious diseases: what can we expect?. *Can Commun Dis Rep*. 2019;45(4):76-80. doi:10.14745/ccdr.v45i04a01
13. Garg S, Jampol LM. Systemic and intraocular manifestations of West Nile virus infection. *Surv Ophthalmol*. 2005;50(1):3-13. doi:10.1016/j.survophthal.2004.10.001
14. Gohari AR, Willson RL, Gitter KA. West nile virus occlusive retinal vasculitis. *Retin Cases Brief Rep*. 2011;5(3):209-212. doi:10.1097/ICB.0b013e3181e18042
15. Hasbun R, Garcia MN, Kellaway J, et al. West Nile virus retinopathy and associations with long term neurological and neurocognitive sequelae. *PLoS One*. 2016;11(3):e0148898. doi:10.1371/journal.pone.0148898
16. Seth RK, Stoessel KM, Adelman RA. Choroidal neovascularization associated with West Nile virus chorioretinitis. *Semin Ophthalmol*. 2007;22(2):81-84. doi:10.1080/08820530701418375
17. Sivakumar RR, Prajna L, Arya LK, et al. Molecular diagnosis and ocular imaging of West Nile virus retinitis and neuroretinitis. *Ophthalmology*. 2013;120(9):1820-1826. doi:10.1016/j.ophtha.2013.02.006
18. Shukla J, Saxena D, Rathinam S, et al. Molecular detection and characterization of West Nile virus associated with multifocal retinitis in patients from southern India. *Int J Infect Dis*. 2012;16(1):e53-e59. doi:10.1016/j.ijid.2011.09.020
19. Khairallah M, Ben Yahia S, Ladjimi A, et al. Chorioretinal involvement in patients with West Nile virus infection. *Ophthalmology*. 2004;111(11):2065-2070. doi:10.1016/j.ophtha.2004.03.032