

A Case That Will Take Your Breath Away: Acquired Methemoglobinemia Related to Trimethoprim-Sulfamethoxazole and Phenazopyridine Ingestion for Treatment of Urinary Tract Infection

Vinay Sharma, MD; Kevin Robertson, MD; Jason Domagalski, MD

ABSTRACT

Trimethoprim-sulfamethoxazole (TMP-SMX) and phenazopyridine are individually associated with methemoglobinemia through a series of altered reduction-oxidation reactions. We report a case of methemoglobinemia associated with concurrent use of TMP/SMX and phenazopyridine in a 70-year-old woman with recurrent urinary tract infections. She presented to the emergency department for worsening back pain in the setting of recurrent urinary tract infections, concerning for pyelonephritis. During her workup, she became acutely hypoxic. The emergency department provider suspected the presence of abnormal hemoglobin. An arterial blood gas showing elevated levels of methemoglobinemia confirmed the suspicion. The combined use of TMP/SMX and phenazopyridine was thought to be the likely etiology of hypoxia. This case highlights the importance of medication management in the geriatric population, as well as the judicious use of antibiotics for urinary tract infections--a common chief complaint in the primary care setting.

INTRODUCTION

Trimethoprim-sulfamethoxazole (TMP-SMX, brand name Bactrim) and phenazopyridine (brand name Pyridium) are individually associated with methemoglobinemia (MHb) through a series of altered reduction-oxidation reactions.¹⁻⁴ MHb occurs when the iron group located within hemoglobin oxidizes from the ferrous state (Fe^{2+}) to the ferric state (Fe^{3+}). MHb has an increased affinity for oxygen that results in decreased dissociation and availability at the tissue level. We report a case of methemoglobinemia associated with concurrent use of TMP/SMX and phenazopyridine in a 70-year-old woman with recurrent urinary tract infections.

• • •

Author Affiliations: Medical College of Wisconsin, Milwaukee, Wisconsin (Sharma, Robertson, Domagalski).

Corresponding Author: Vinay Sharma, MD, Medical College of Wisconsin, 3024 N 86th St, Milwaukee, WI 53222; email Vks21090@gmail.com.

CASE PRESENTATION

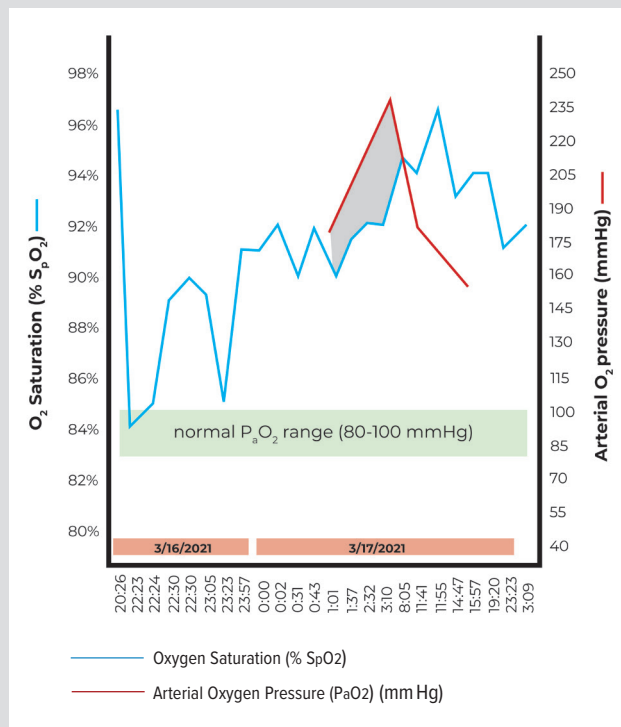
A 70-year-old woman with a past medical history of hypertension, asthma, recurrent urinary tract infections (UTI), alcohol abuse, a remote history of morphine overdose, and active cannabis use presented to the emergency department (ED) for dysuria and back pain. She described a non-radiating, constant, 9/10 burning back pain with urination that improved with marijuana use. For her recurrent UTIs, she had been taking prophylactic Bactrim, half a tab every day, prescribed by her primary care provider for the previous 4 months. For pain control, she also was prescribed

Pyridium (unknown dose) to use as needed for pain control. She had been intermittently using Pyridium for the past 3 to 4 months. The day prior to presenting to the ED, in addition to her prophylactic doses of TMP/SMX, she took 2 additional tablets (unknown dose) and another 2 tablets the day she presented to the ED. She obtained these medications from her sister, who had unused medication.

The patient's initial physical exam showed concerns for acute pyelonephritis/urosepsis. Her labs did not show leukocytosis, anemia, or electrolyte derangements. Computed tomography of the abdomen and pelvis was unremarkable. For pain, she received a single injection of 4 mg morphine.

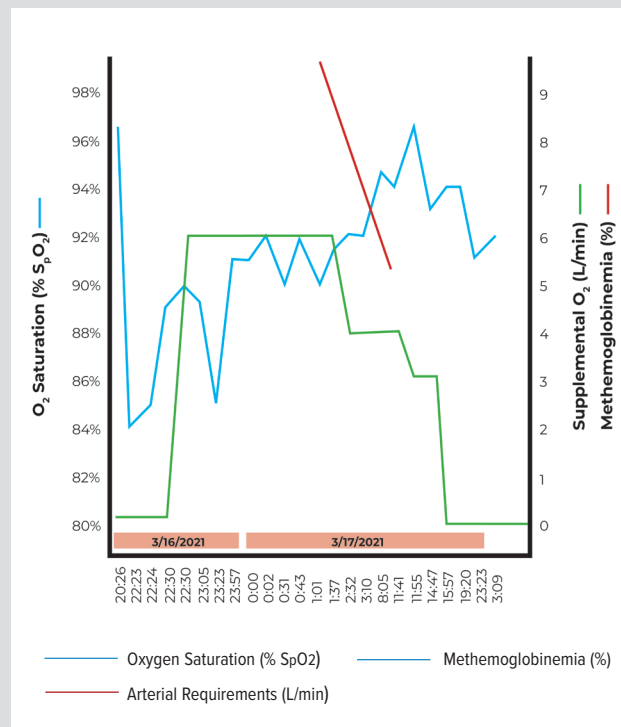
While in the ED, the patient suddenly became hypoxic, requiring 6 liters of oxygen delivered via OxyMask (Figure 1). A chest x-ray and computed tomography pulmonary angiogram protocol were negative for any acute process. She attempted multiple weaning trials with no improvement in hypoxia. An arterial blood gas (ABG) test showed a MHb level of 9.4% and a PaO_2 of 176 mm Hg (normal MHb <3%, PaO_2 80-100 mm Hg). The ED provid-

Figure 1. Illustrating the Saturation Gap



Early in the patient's hospital course, she had very high levels of arterial oxygen pressures (red line) and persistently low oxygen saturations (blue line). The shaded region represents the "saturation gap," which can be an early sign of methemoglobinemia.

Figure 2. Oxygen Requirements Throughout Hospital Course



The patient's oxygen saturation (blue line) acutely dropped early in her emergency department course, requiring supplemental oxygen (green line). As methemoglobinemia levels decreased (red line), oxygen use decreased and saturations improved.

ers contacted poison control, which recommended admission with serial ABGs, complete blood cell counts, and vital signs until she could breathe on room air. The patient's breathing improved, and she weaned off oxygen to room air by time of discharge. Serial ABGs showed decreasing MHB levels (Figure 1). We attributed the cause of MHB to the concurrent use of phenazopyridine and TMP-SMX.

DISCUSSION

The mechanism underlying TMP/SMX and phenazopyridine-associated MHB is not well understood. It is hypothesized these medications interfere with the nicotinamide adenine dinucleotide (NAD) + hydrogen (H)/nicotinamide adenine dinucleotide phosphate (NADPH) reductase pathway, resulting in disrupted oxidation/reduction reactions.³

Symptoms of MHB are dependent on blood concentrations. Symptoms of patients with concentrations less than 10% range from asymptomatic to mild dyspnea. Some literature has shown patients are asymptomatic until levels are greater than 40%.⁵ The most recognized symptom of MHB is cyanosis. Other symptoms include headaches, fatigue, worsening dyspnea, and chocolate brown blood. Seizure, coma, and death are all complications of MHB when concentrations are above 50%.⁶ Treatment for MHB is methylene blue or ascorbic acid.⁶

A key diagnostic finding in the presentation of MHB is recognizing the "saturation gap" (Figure 2). The first indication of a saturation gap occurs when patients are placed on oxygen and saturations do not improve.⁶⁻⁸ An ABG confirms the presence of a saturation gap, which shows high levels of PaO₂ with consistently low hemoglobin saturations.

The patient presented in this report developed acute hypoxia in the setting of long-term TMP/SMX and phenazopyridine use for recurrent urinary tract infections. She did receive a dose of morphine in the ED, which could have contributed to her hypoxia; however, in the absence of other opioid-related symptoms, this is less likely. She also has asthma; however, her physical exam was not consistent with an exacerbation. She was negative for pulmonary embolism and SARS-CoV-2. Regarding her MHB percentage, symptoms are typically seen above 10%. Her asthma and marijuana and morphine use, while not actively contributing to her current clinical presentation, likely resulted in a form of chronic lung disease that predisposed her to symptoms of MHB at lower levels.⁹ In the absence of other contributing medical history or a causative agent, the combined use of TMP/SMX and phenazopyridine was the likely etiology of her acute hypoxia (Naranjo Adverse Drug Reaction Probability Scale¹⁰ Score of 7 [probable]).¹¹

While prolonged use of TMP/SMX and phenazopyridine is more likely to result in MHb, as we saw in this case, a slight increase in dose for a short period of time could be enough to result in symptoms.¹¹⁻¹³ This further highlights the need for primary care clinicians to be vigilant in medication management for patients, even for somewhat routine treatments or over-the-counter medications.

Of note, several geriatric patients have some extent of kidney disease, which can impact dosing of TMP/SMX and phenazopyridine. The Beer's List advises to use TMP/SMX with caution in patients taking angiotensin converting enzyme inhibitors, angiotensin receptor blockers, or warfarin, common medications in the geriatric population.¹⁴ This also highlights the need for patients to work with their provider for medication adjustments and to ensure they are safe.

CONCLUSIONS

UTIs are common occurrences in the general population and often are treated empirically with TMP/SMX, while phenazopyridine is available over the counter. With changing demographics in the American population and a growing geriatric percentage, recurrent UTIs may become a more common complaint and prophylaxis more widespread. While acute hypoxia due to MHb is rare, given the widespread use of these medications in the outpatient setting, it is important for providers to be aware of the association and educate patients about potential risk.

Financial Disclosures: Dr Domagalski reports having received payment or honoraria from the American Academy of Family Physicians (AAFP) for speaking engagements and serves as chair of the AAFP Family Medicine Experience Faculty Advisory Board.

Funding/Support: None declared.

REFERENCES

1. Kawasumi H, Tanaka E, Hoshi D, Kawaguchi Y, Yamanaka H. Methemoglobinemia induced by trimethoprim-sulfamethoxazole in a patient with systemic lupus erythematosus. *Intern Med.* 2013;52(15):1741-1743. doi:10.2169/internalmedicine.52.0247
2. Shahani L, Sattovia S. Acquired methaemoglobinemia related to phenazopyridine ingestion. *BMJ Case Rep.* 2012;2012:bcr2012006756. doi:10.1136/bcr-2012-006756
3. Murphy T, Fernandez M. Acquired methemoglobinemia from phenazopyridine use. *Int J Emerg Med.* 2018;11(1):45. doi:10.1186/s12245-018-0208-5
4. Randazzo GP, Ford EA, Glauser FL. Methemoglobinemia caused by acute overdosage of phenazopyridine. *West J Med.* 1975;122(5):427-429.
5. Tasci C, Nevruz O, Candir N, Bilgic H. A methemoglobinemia case who was previously diagnosed and treated as asthma. *Respir Med Case Rep.* 2012;6:11-12. doi:10.1016/j.rmcr.2012.08.002
6. Iolascon A, Bianchi P, Andolfo I, et al. Recommendations for diagnosis and treatment of methemoglobinemia. *Am J Hematol.* 2021;96(12):1666-1678. doi:10.1002/ajh.26340
7. Wright RO, Lewander WJ, Woolf AD. Methemoglobinemia: etiology, pharmacology, and clinical management. *Ann Emerg Med.* 1999;34(5):646-656. doi:10.1016/s0196-0644(99)70167-8
8. Furuta K, Ikeo S, Takaiwa T, et al. Identifying the cause of the "saturation gap": two cases of dapsone-induced methemoglobinemia. *Intern Med.* 2015;54(13):1639-1641. doi:10.2169/internalmedicine.54.3496
9. Skold A, Cosco DL, Klein R. Methemoglobinemia: pathogenesis, diagnosis, and management. *South Med J.* 2011;104(11):757-761. doi:10.1097/SMJ.0b013e318232139f
10. Doherty MJ. Algorithms for assessing the probability of an adverse drug reaction. *Respir Med CME.* 2009;2:63-67.
11. Belhekar MN, Taur SR, Munshi RP. A study of agreement between the Naranjo algorithm and WHO-UMC criteria for causality assessment of adverse drug reactions. *Indian J Pharmacol.* 2014;46(1):117-120. doi:10.4103/0253-7613.125192
12. Williamson K, Htet N, Nanini S. Methemoglobinemia from prolonged therapeutic use of phenazopyridine. *Ann Clin Case Rep.* 2016;1:1085.
13. Agrawal A, Davis N, Hsieh R, Stallard S. Methemoglobinemia with chronic phenazopyridine ingestion. *BMJ Case Rep.* 2019;12(2):e227538. doi:10.1136/bcr-2018-227538
14. Therapeutic Research Center. Potentially harmful drugs in the elderly: Beers List. March 2019. Accessed August 14, 2022. <https://www.pharmacyquality.com/wp-content/uploads/2019/05/Beers-List-350301.pdf>

advancing the art & science of medicine in the midwest

WMJ

WMJ (ISSN 1098-1861) is published through a collaboration between The Medical College of Wisconsin and The University of Wisconsin School of Medicine and Public Health. The mission of *WMJ* is to provide an opportunity to publish original research, case reports, review articles, and essays about current medical and public health issues.

© 2023 Board of Regents of the University of Wisconsin System and The Medical College of Wisconsin, Inc.

Visit www.wmjonline.org to learn more.