

# Acute Myelomonocytic Leukemia Presenting as Fournier's Gangrene

Sofie Kjellesvig, MD; Emelyn Zaworski, MD; Antoine N. Saliba, MD

## ABSTRACT

**Introduction:** Acute myelomonocytic leukemia is a type of acute myeloid leukemia with monocytic expansion. Both the disease and its treatment can be immunocompromising. Immunocompromised patients are more susceptible to infections, such as Fournier's gangrene, a rare necrotizing infection of the groin.

**Case Presentation:** A 56-year-old male presented to the emergency department with abdominal pain, leukocytosis, and perineal ecchymosis. Overnight, his perineal discoloration and tenderness worsened. He underwent irrigation and debridement for Fournier's gangrene and received broad-spectrum antimicrobial therapy. Subsequent workup revealed acute myeloid leukemia with leukemia cutis and central nervous system involvement, necessitating chemotherapy initiation prior to complete wound healing.

**Discussion/Conclusions:** This case highlights the challenges in the diagnosis and management of acute leukemia in the setting of a concomitant life-threatening soft tissue infection, as both the hematologic disease and treatment thereof can exacerbate infectious complications.

## INTRODUCTION

Acute myeloid leukemia (AML) encompasses a heterogeneous range of aggressive hematologic malignancies characterized by proliferation of immature myeloid cells (blasts) making up  $\geq 20\%$  of cells in the bone marrow or peripheral blood.<sup>1,2</sup> Acute myelomonocytic leukemia (AMML) is a rare type of AML distinguished by an increase in cells of monocytic lineage, which may occur de novo or transform from an underlying myelodysplastic syndrome.<sup>2</sup> AML can present asymptotically, with constitutional symptoms (fevers, night sweats, fatigue, weight loss), or with sequelae of pancytopenia (infections, bleeding, bruising).<sup>1</sup> Since both AML

itself and its treatment can cause immunosuppression, these patients are susceptible to opportunistic infections as well as life-threatening infections with common pathogens.

Fournier's gangrene is a necrotizing fasciitis of the groin that develops either spontaneously or secondary to external trauma.<sup>3</sup> Patients typically present with local pain, swelling, and erythema as well as systemic symptoms, including fevers and chills. Cutaneous discoloration or crepitus on exam often portends a more advanced disease state. If there is suspicion for Fournier's gangrene, radiographic studies may reveal air in the soft tissue. However, imaging should not delay treatment due

to the high morbidity and mortality of disease. The highest-risk groups of patients experience up to a 75% risk of death, and delaying treatment has been shown to significantly increase that risk.<sup>4</sup> Urgent surgical debridement is necessary for both diagnostic and therapeutic purposes.<sup>4</sup>

This report presents a case of AMML with leukemic involvement of the skin and central nervous system, complicated by Fournier's gangrene, which required extensive surgical debridement. Its purpose is to highlight the rarity of Fournier's gangrene as a presentation of AMML and the challenges of effectively treating both the malignancy and infection.

## CASE PRESENTATION

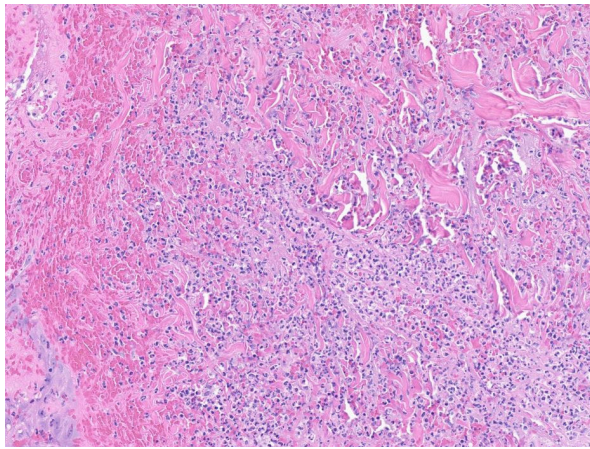
A 56-year-old male presented to the emergency department with abdominal pain, diarrhea, rigors, chills, night sweats, and appetite loss for 2 weeks. Labs revealed a white blood cell count of  $38.8 \times 10^3/\mu\text{L}$  (reference range:  $4.5 \times 10^3/\mu\text{L} - 11 \times 10^3/\mu\text{L}$ ) with elevated myelocytes, metamyelocytes, monocytes, and 8%

• • •

**Author Affiliations:** Medical College of Wisconsin—Central Wisconsin, Wausau, Wisconsin (Kjellesvig, Zaworski); Division of Hematology, Mayo Clinic, Rochester, Minnesota (Saliba).

**Corresponding Author:** Sofie Kjellesvig, MD; email [sofiekjellesvig@gmail.com](mailto:sofiekjellesvig@gmail.com); ORCID ID 0000-0003-3338-0647

**Figure 1.** Surgical Pathology Slide From Biopsy During Irrigation and Debridement Procedure Stained With Hematoxylin and Eosin

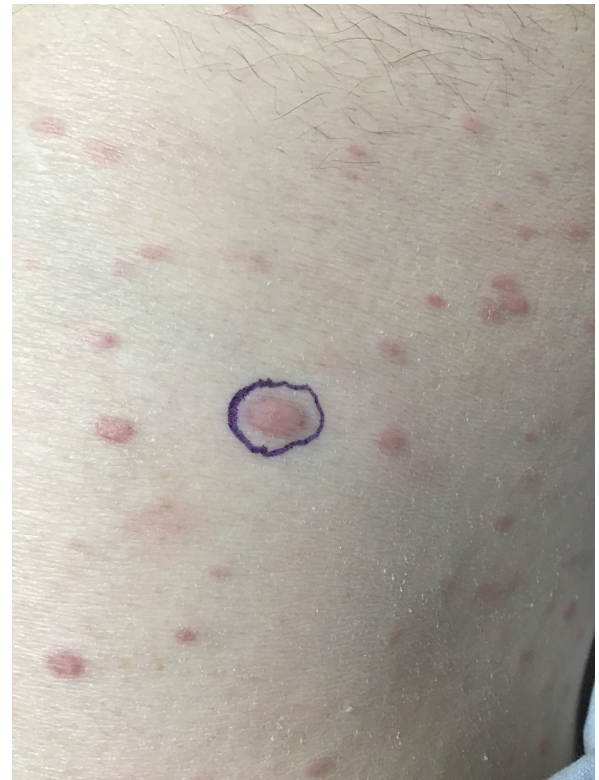

Pathology demonstrated skin and subcutaneous tissue with acute inflammation and necrosis, consistent with Fournier's gangrene.

blasts, as well as anemia and mild thrombocytopenia. He was noted to have a perineal skin lesion that rapidly extended overnight from the perineum to the scrotum with worsening violaceous discoloration and severe tenderness to palpation. Broad-spectrum antibiotics were initiated. Given rapid progression and high clinical suspicion for Fournier's gangrene, urgent irrigation and debridement were performed. During patient positioning, nodular lesions with black hemorrhagic rings were noted over the bilateral ischial tuberosities and were biopsied. Intraoperative findings were concerning for early Fournier's gangrene with mild skin necrosis and significant tissue edema without frank purulence. Skin biopsy later returned as leukemia cutis. Wound culture grew polymicrobial colonies, and blood cultures subsequently grew *Clostridium septicum*.

Initial bone marrow biopsy and flow cytometry findings were consistent with AML with monocytic differentiation, specifically AMML. Marrow cellularity was 100% with trilineage hematopoietic maturation, including granulocytic hyperplasia, atypical megakaryocytes, monocytosis, and 59% blasts and promonocytes. Atypical-appearing peripheral blood monocytes were also present. Conventional cytogenetic studies showed a clonal trisomy 8. Next generation sequencing using a myeloid malignancies gene panel revealed pathogenic variants in *NPM1*, *U2AF1*, *DNMT3A*, and *TET2*. Blast percentage was stable at this time, but the patient's Fournier's gangrene had not been fully controlled, necessitating further surgical intervention. Antimicrobial and tumor lysis syndrome prophylaxis medications were initiated, but leukemia-directed myelosuppressive treatment was delayed to prioritize infection management. Several irrigation and debridement procedures were performed, and a loop sigmoid colostomy was created to facilitate wound healing. A vacuum-assisted wound clo-

**Figure 2.** Photo of Widespread Eruption of Leukemia Cutis Lesions Over the Patient's Trunk



sure device also was used to further optimize wound care. Surgical pathology confirmed the working diagnosis of Fournier's gangrene (Figure 1). The leukocytosis temporarily resolved with these interventions. Broad-spectrum antibiotics were discontinued after 29 days, and prophylactic levofloxacin was started in the setting of neutropenia. Cyto-reductive therapy with hydroxyurea eventually was initiated after recurrence of leukocytosis with circulating blasts. As the patient's wound continued to heal, he developed an eruption of violaceous papules and nodules involving most of his body (Figure 2). Punch biopsy confirmed the lesions to be leukemia cutis.

As the patient was undergoing staging, there was a concern for wound dehiscence, and he started undergoing hyperbaric oxygen therapy (HBOT) to expedite healing prior to initiation of chemotherapy. One week into HBOT, a screening lumbar puncture was performed to evaluate for leukemic involvement of the central nervous system (CNS). Lumbar puncture showed rare, atypical monocytic cells, confirming CNS involvement. Therefore, HBOT was discontinued and leukemia-directed therapy was started. The patient received intrathecal cytarabine and methotrexate for his CNS disease. The risk of exacerbating his Fournier's gangrene with intensive systemic chemotherapy with cytarabine and an anthracycline was felt to be too high. Additionally, given myelodysplasia-related gene changes, a com-

bination of a hypomethylating agent (decitabine) and venetoclax was felt to be an effective, safer option.

The patient completed 1 cycle of decitabine and venetoclax, during which time his perineal wounds healed well, though his hospital course was complicated by severe mucositis. His leukemia cutis improved quickly during this time. Following the first cycle, his AML was in complete remission, but an NPM1 qRT-PCR assay was positive for measurable residual disease. As his CNS leukemic involvement was difficult to control with intrathecal therapy alone and as his surgical wounds had healed, high-dose cytarabine – with a dose reduction to 2.25 g/m<sup>2</sup> – was given for 2 cycles, in a fashion similar to consolidation after successful induction therapy. Following this treatment, his CNS leukemic involvement cleared, but his leukemia cutis and bone marrow disease relapsed. He decided to pursue hospice care at that time and eventually died of relapsed leukemia.

## DISCUSSION

This case demonstrates the difficulty of identifying Fournier's gangrene at an early stage. Often mistaken for ecchymosis, Fournier's gangrene may not be identified until it reaches a more fulminant state. The causative agent in this patient was *C septicum*, identified on blood cultures. *C septicum* is associated with spontaneous rather than traumatic gangrene.<sup>3</sup> *C septicum* myonecrosis is known to be highly associated with malignancy (up to 80%) and immunosuppression.<sup>5,6</sup> In this patient, it is possible that perineal leukemia cutis served as a nidus for infection in the setting of immunosuppression secondary to acute leukemia. In patients who develop spontaneous gas gangrene, it is especially important to evaluate for an underlying immunocompromising condition, such as malignancy. Other case reports have documented examples of Fournier's gangrene as a presenting symptom in patients who were ultimately diagnosed with hematologic malignancies, commonly AML, or as a complication of treatment for these disorders.<sup>7-11</sup> Of these reports, only two describe AMML presenting as Fournier's gangrene, and neither patient survived; one died within days, only receiving supportive care, and the other passed away during chemotherapy initiation.<sup>10,11</sup> The case we present is unique in that this patient completed multiple cycles of chemotherapy and was able to achieve healing of his extensive surgical wounds and remission of his bone marrow disease for a period of time.

This patient's AML morphology was most consistent with AMML. Distinguishing features of his molecular landscape were somatic mutations of *NPM1* and *U2AF1*.<sup>12</sup> *NPM1* is an AML-defining molecular abnormality regardless of blast percentage, per the World Health Organization 2022 diagnostic criteria.<sup>2</sup> *U2AF1* mutations typically are seen in AML with myelodysplasia-related changes and are associated with AML that transformed from myelodysplastic syndrome as opposed to de novo AML.<sup>2,12</sup> These findings suggest that the AML likely progressed from underlying

myelodysplastic syndrome or chronic myelomonocytic leukemia. The remainder of the genetic and chromosomal abnormalities also support an AML diagnosis, though trisomy 8 also is seen in other myeloproliferative disorders.<sup>13</sup> His leukocytosis, monocytic differentiation, and extramedullary involvement were all risk factors for leukemic CNS involvement. A rare manifestation of AML also seen in this patient was leukemia cutis: lesions resulting from neoplastic skin infiltration. Among AML subtypes, leukemias with prominent monocytic or myelomonocytic differentiation are more commonly associated with leukemia cutis.<sup>14,15</sup> The wide variability of these lesions (most commonly nodules, papules, and plaques) makes their identification as manifestations of a hematologic malignancy challenging without a prior diagnosis.<sup>12</sup> In patients with known or suspected leukemia, obtaining a biopsy of new skin lesions is recommended due to the prognostic implications of leukemia cutis.<sup>15</sup> The presence of leukemia cutis, CNS disease, and somatic mutation of *U2AF1* were all poor prognostic indicators for this patient.<sup>12,14</sup>

In this patient with Fournier's gangrene and concomitant AML, leukemia-directed treatment was delayed by 2 months to manage the rapid infection progression. His Fournier's gangrene was managed with irrigation/debridement procedures, negative pressure therapy, and antibiotics, followed by HBOT due to concern for wound dehiscence. Wound healing was monitored closely because although it was important to start chemotherapy in a timely manner, receiving myelosuppressive treatment with an open wound would have significantly increased his risk of further infectious complications.

As healing progressed, routine lumbar puncture was performed to screen for blasts in his cerebrospinal fluid. Asymptomatic CNS leukemic involvement was discovered, necessitating urgent modification of therapeutic strategy. Leukemia-directed therapy took precedence over infection control to prevent neurological decompensation. Intrathecal chemotherapy with cytarabine and methotrexate was initiated along with systemic agents. Decitabine and venetoclax were chosen in lieu of aggressive systemic chemotherapy, which was felt to be too dangerous given the need for continued wound healing. When he achieved remission but was found to have measurable residual disease, his wounds had healed well enough that systemic cytarabine therapy was started. Although this treatment eradicated his CNS disease, his AML relapsed in the bone marrow and skin following 2 cycles, and at that time he chose to transition to hospice. Extensive and frequent communication between the internal medicine, surgery, and hematology teams was critical to coordinating and adjusting this patient's treatment plan based on the most pressing concern at each point during his care.

## CONCLUSIONS

This patient exhibited two easily overlooked, consequential physical exam findings: (1) bruise-like perineal skin changes

from Fournier's gangrene and (2) leukemia cutis, an adverse prognostic factor. Without any known immunocompromising condition, it was paramount to uncover predisposing factors for his development of nontraumatic Fournier's gangrene, such as AML or another hematologic malignancy. In this patient, infection control was prioritized initially; however, upon discovering CNS involvement of his AML, leukemia-direct therapy was initiated despite the potential for wound healing complications. This strategy enabled the patient to achieve complete bone marrow remission after 1 cycle and allowed his surgical wounds to heal before adjusting his chemotherapy regimen to effectively address his residual CNS disease. After 2 cycles, however, his bone marrow disease relapsed and he elected to transition to hospice care before passing away.

Ultimately, this case highlights the importance of multidisciplinary collaboration when caring for a patient with concomitant, life-threatening conditions that are intertwined but disparately managed.

**Funding/Support:** None declared.

**Financial Disclosures:** None declared.

**Consent:** Patient signed a standard Mayo Clinic authorization to use deidentified photos for educational and publication purposes.

---

## REFERENCES

1. Newell LF, Cook RJ. Advances in acute myeloid leukemia. *BMJ*. 2021;375:n2026. doi:10.1136/BMJ.N2026
2. Khoury JD, Solary E, Abla O, et al. The 5th edition of the World Health Organization classification of haematolymphoid tumours: myeloid and histiocytic/dendritic neoplasms. *Leukemia*. 2022;36(7):1703-1719. doi:10.1038/s41375-022-01613-1
3. Srivastava I, Aldape MJ, Bryant AE, Stevens DL. Spontaneous *C. septicum* gas gangrene: a literature review. *Anaerobe*. 2017;48:165-171. doi:10.1016/J.ANAEROBE.2017.07.008
4. Thwaini A, Khan A. Fournier's gangrene and its emergency management. *Postgrad Med J*. 2006;82:516-519. doi:10.1136/pgmj.2005.042069
5. Chew SSB, Lubowski DZ. *Clostridium septicum* and malignancy. *ANZ J Surg*. 2001;71(11):647-649. doi:10.1046/J.1445-1433.2001.02231.X
6. Alpern RJ, Dowell VR. Clostridium septicum infections and malignancy. *JAMA*. 1969;209(3):385-388. doi:10.1001/JAMA.1969.03160160021004
7. Berg A, Armitage JO, Burns CP. Fournier's gangrene complicating aggressive therapy for hematologic malignancy. *Cancer*. 1986;57(12):2291-2294. doi:10.1002/1097-0142(19860615)57:12<2291::aid-cnrc2820571210>3.0.co;2-4
8. Faber HJ, Girbes ARJ, Daenen S. Fournier's gangrene as first presentation of promyelocytic leukemia. *Leuk Res*. 1998;22(5):473-476. doi:10.1016/S0145-2126(98)00025-3
9. Finkelstein ER, Perez-Quirante F, Panthaki Z. Reconstruction of the scrotum with bilateral gracilis muscle rotational flaps in a patient with acute myeloid leukemia complicated by Fournier's gangrene. *Cureus*. 2022;14(6). doi:10.7759/CUREUS.25988
10. Mostaghim A, Dhanani M, Ingalls RR. Fournier's gangrene as an initial manifestation of acute promyelocytic leukemia: a case report and review of the literature. *SAGE Open Med Case Rep*. 2019 Mar 1;7:2050313X19834425. doi: 10.1177/2050313X19834425
11. Mosayebi Z, Omidian A, Movahedian AH, Kompani F, Hosseininoddeh SS. Fournier's Gangrene in a Neonate With Acute Myeloid Leukemia: A Case Report. *Iran J Pediatr*. 2016;26(3):e4537. doi:10.5812/ijp.4537
12. Döhner H, Wei AH, Appelbaum FR, et al. Diagnosis and management of AML in adults: 2022 recommendations from an international expert panel on behalf of the ELN. *Blood*. 2022;140(12):1345-1377. doi:10.1182/BLOOD.2022016867
13. Gibson CJ, Ebert BL, Steensma DP. Myelodysplastic syndromes. In: Hoffman R, Benz EJ, Silberstein LE, et al. (eds). *Hematology: Basic Principles and Practice*. 7th ed. Elsevier; 2018:944-969.e13. Accessed March 13, 2023. doi:10.1016/B978-0-323-35762-3.00060-3
14. Osmola M, Gieriej B, Kłosowicz A, et al. Leukaemia cutis for clinicians, a literature review. *Postepy Dermatol Alergol*. 2021;38(3):359-365. doi:10.5114/ADA.2021.107923
15. Bakst RL, Tallman MS, Douer D, Yahalom J. How I treat extramedullary acute myeloid leukemia. *Blood*. 2011;118(14):3785-3793. doi:10.1182/BLOOD-2011-04-347229

advancing the art & science of medicine in the midwest

**WMJ**

*WMJ* (ISSN 1098-1861) is published through a collaboration between The Medical College of Wisconsin and The University of Wisconsin School of Medicine and Public Health. The mission of *WMJ* is to provide an opportunity to publish original research, case reports, review articles, and essays about current medical and public health issues.

© 2024 Board of Regents of the University of Wisconsin System and The Medical College of Wisconsin, Inc.

**Visit [www.wmjonline.org](http://www.wmjonline.org) to learn more.**