

Peripartum Uterine Clostridial Myonecrosis: A Report of Two Fatal Cases

Laura Jacques, MD; Bridget Kelly, MD; John Soehl, MD; Matthew Wagar, MD; Janine Rhoades, MD; Elise S. Cowley, BS; Peter G. Pryde, MD; Abigail Cutler, MD; David Eschenbach, MD

ABSTRACT

Introduction: Uterine clostridial myonecrosis is a rare infection associated with a high mortality rate. This report presents 2 cases of maternal mortality resulting from peripartum clostridial myonecrosis of the uterus.

Case Presentation: Case 1 is a 30-year-old woman (nullipara) who presented in labor at term with an intra-amniotic infection and fetal demise. She rapidly developed septic shock, and cesarean hysterectomy was performed for a suspected necrotizing uterine infection later identified to be *Clostridium septicum*. Case 2 is an adolescent who presented in septic shock following first trimester medication abortion and died during emergent exploratory laparotomy; cultures grew *Clostridium sordellii*. Both patients expired within 18 hours of hospital admission.

Discussion: Given the rapidly progressive course of clostridial infections, maintaining a high index of suspicion is imperative for ensuring timely diagnosis and effective treatment. Prompt recognition of clinical features associated with clostridial myonecrosis—abdominal pain, tachycardia, leukocytosis and hyponatremia—is essential in preventing mortality. The utilization of point-of-care ultrasound may expedite the diagnosis of uterine myonecrosis. When uterine myonecrosis is suspected, immediate initiation of penicillin-based antibiotics, alongside clindamycin, and aggressive surgical intervention including hysterectomy are essential for ensuring survival. Although the decision to perform a hysterectomy can be challenging, especially in cases involving child-bearing-aged patients, it is a vital step to avert a fatal outcome.

Conclusions: By presenting these cases, we aim to raise awareness of this uncommon, but highly lethal infection to expedite diagnosis and treatment to improve patient outcomes.

• • •

Author Affiliations: Department of Obstetrics and Gynecology, University of Wisconsin School of Medicine and Public Health (UWSMPH), Madison, Wisconsin (Jacques, Kelly, Wagar, Rhoades, Cutler); Department of Maternal Fetal Medicine, Women and Infants Hospital, Providence Rhode Island (Soehl); Department of Bacteriology, University of Wisconsin-Madison, Madison, Wisconsin (Cowley); Microbiology Doctoral Training Program, UW-Madison, Madison, Wisconsin (Cowley); Madison Anesthesiology Consultants, Madison, Wisconsin (Pryde); Department of Obstetrics and Gynecology, University of Washington, Seattle, Washington (Eschenbach).

Corresponding Author: Laura Jacques, MD, Department of Obstetrics and Gynecology, University of Wisconsin School of Medicine and Public Health, McConnell Hall, 4th Floor, 1010 Mound St, Madison, WI 53715, email laura.jacques@wisc.edu; ORCID ID 0000-0003-2343-8358

INTRODUCTION

Severe sepsis from intra-amniotic infection (IAI) is a rare but devastating complication of both childbirth and abortion.¹⁻⁴ Intra-amniotic infection is typically polymicrobial, and isolation of a single causative bacterial species is uncommon.⁵ The exception is IAI due to toxin-producing bacteria like *Clostridium* and Group A *Streptococcus* (GAS) which, even in isolation, can cause lethal necrotizing infections. Nearly all maternal infectious deaths today in developed countries are caused by these organisms.⁶⁻⁸ Though uncommon, clostridial myonecrosis (gas gangrene) of the uterus can result from prolonged rupture of membranes, retained products of conception, and post-abortive sequelae.⁹⁻¹¹ We describe 2 cases of maternal death due to peripartum clostridial myonecrosis of the uterus.

CASE PRESENTATIONS

Case 1: *Clostridium septicum*

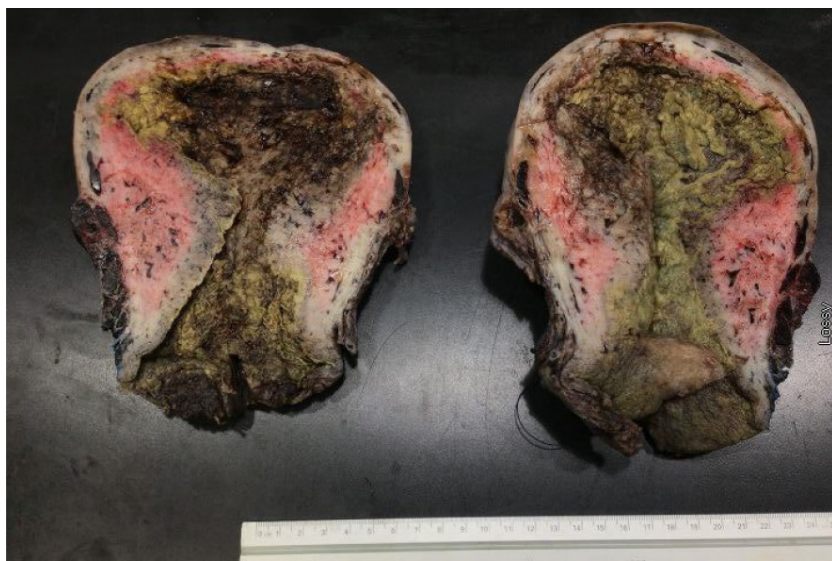A 30-year-old gravida 2, para 0010 (G2P0010) female without any prenatal care at approximately 42 weeks gestation presented with ruptured membranes and an intrauterine fetal demise in breech presentation. Vital signs were remarkable for fever of 38.2°C, pulse of 127 beats per minute (bpm), and hypertension with blood pressure (BP) of 167/81. Laboratory evaluation including a complete blood cell count (CBC), comprehensive metabolic panel (CMP), and urine protein to creatinine ratio (P:C) showed leukocytosis 19.6 10³/μL, hyponatremia 126 mmol/L, and urine P:C 0.57, while creatinine, aspartate aminotransferase (AST),

alanine aminotransferase (ALT), lactate, and platelet counts were normal. She had no known history of hypertension and was treated for preeclampsia with severe features with a 4-gram bolus and then 2-gram per hour infusion of magnesium sulfate and 1 dose of 20 mg intravenous (IV) labetalol. Her BP responded initially to 134/77, and she never required another dose of labetalol. She received an epidural for pain control but initially declined labor augmentation, antibiotic treatment for presumed IAI, or imaging.

Two hours after admission, she accepted and received ampicillin and gentamicin; her fever defervesced, and her tachycardia resolved. Vitals signs were recorded every 15 minutes and she remained normotensive with adequate urine output of 80 mL/hour over the next 4 hours. Labor progressed without augmentation and contractions were detected every 3 minutes on tocometry.

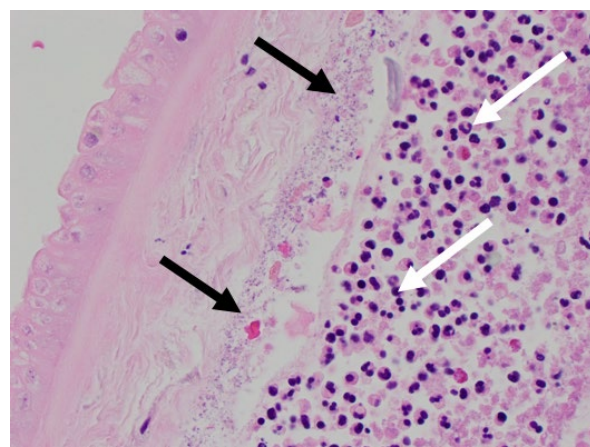
Seven hours after admission, she reported increasing abdominal pain despite the epidural. Her condition acutely deteriorated, with vital signs 15 minutes before decompensation showing BP 101/65, pulse 88 bpm, and oxygen saturation 96%. Then, 15 minutes later, her BP and oxygen saturation dropped to 68/37 and 91%, respectively, while her pulse remained 85 bpm. On physical examination, she was found to be newly lethargic and her fundal height, measured at 37 cm on admission, was palpated at the level of her diaphragm. Due to abdominal pain and the rapid increase in her fundal height, a bedside transabdominal ultrasound was attempted to assess the uterus and abdomen for signs of abruption and blood accumulation, but the presence of diffuse high-amplitude echoes and myometrial shadowing made visualization challenging. Chest x-ray and bedside echocardiogram were without acute findings. Laboratory evaluation was now significant for a white blood cell (WBC) count of $24.6 \times 10^3/\mu\text{L}$, hemoglobin 11.9 g/dL, creatinine 1.34 mg/dL, sodium 128 mmol/L, and magnesium 7.4 mg/dL. Her antibiotics were broadened to piperacillin/tazobactam and vancomycin, and she initially responded to IV blood pressure support. She was now completely dilated and plus 2 station and began pushing for an attempted breech vaginal delivery. Her condition worsened during 15 minutes of pushing with minimal descent of the fetal breech, so a vertical midline cesarean delivery under general anesthesia was performed. Upon entry into the abdomen, the uterus was markedly enlarged and edematous with diffuse mottling. A classical hysterotomy, which notably did not bleed, caused the eruption of large vol-

Figure 1. Gross Uterine Pathology



Gross uterine specimen for Case 1 demonstrating diffuse decidual and myometrial necrosis with complete cervical necrosis.

Figure 2. Placental Pathology



Chorioamnionitis associated with Case 1 with gram-variable rods present within intermembranous space (black arrows). Polymorphonuclear granulocytes present diffusely within chorion (white arrows).

ume foul-smelling gas. A demised fetus, which weighed 6800 grams due to remarkable edema and gaseous distension, was delivered. Hysterectomy was completed to obtain source control of the infection. Disseminated intravascular coagulation was diagnosed intraoperatively with an international normalized ratio (INR) of 4.0 and an undetectable fibrinogen level.

She was transferred to the intensive care unit postoperatively; 2 hours later, she experienced cardiac arrest, was unable to be resuscitated, and was pronounced dead. Uterine and placental cultures grew *Escherichia coli* and *Clostridium septicum*; 2 sets of

Table. Unique (White) and Shared (Gray) Features of *Clostridium septicum* and *Clostridium sordellii*

Clinical Considerations					
Organism	Pathogenesis	Clinical Exam	Laboratory	Imaging	Management
<i>C septicum</i>	4 unique toxins	Fever Hemorrhagic bullae Soft tissue crepitations Right heart	↑ White blood cell 15-30 10 ³ /μL Coagulopathy ↓ Hemoglobin ↓ Platelets ↓ Fibrinogen ↑ INR	Echocardiogram Right heart failure	Broad spectrum antibiotics • Clindamycin AND • Piperacillin-tazobactam
Both	Toxin production Ascending infection from vaginal or rectal flora	Pain out of proportion to exam Shock Refractory hypotension Tachycardia Oliguria	↑ White blood cell ↑ Creatine kinase ↑ Lactate ↑ Creatinine ↑ Liver function tests ↓ Sodium Gram stain Gram+/Gram-variable rods ↓ Neutrophils	CT scan/ultrasound Myometrial gas	Hemodynamic stabilization • Multidisciplinary care team • Adequate intravenous and central line access • Aggressive fluid and pressor support
<i>C sordellii</i>	7 unique toxins	No fever Capillary leak syndrome Large volume	↑↑↑ White blood cell 50-200 10 ³ /μL Hemoconcentration	Fast scan/CT scan Ascites	Early and aggressive source control • Consider hysterectomy • Consider unilateral or bilateral salpingoophorectomy

Abbreviations: CT, computed tomography.

Bold text represents key features.

peripheral blood cultures collected on admission had no growth. Pathology exam of the uterus demonstrated extensive decidual and myometrial necrosis (Figure 1). Placental pathology revealed acute necrotizing chorioamnionitis with Gram-variable rods in the intermembranous space (Figure 2). Her family declined autopsy of the patient and fetus.

Case 2: *Clostridium sordellii*

The second case is an adolescent female (primigravida) who presented to the emergency department (ED) with worsening lower abdominal pain 8 days after initiating medication abortion with mifepristone and misoprostol at 8 weeks' gestation. She had normal vital signs and laboratory evaluation, except a WBC count of 23.9 10³/μL. Ultrasound showed vascular, echogenic material in the endometrial cavity presumed to be retained products of conception, so she underwent an uncomplicated manual vacuum aspiration in the ED and was discharged home.

She returned to the ED the next day with worsening abdominal pain and altered mental status. She was hypotensive (BP 30/15 mmHg) and tachycardic (heart rate 110 bpm) but afebrile and oxygenating normally. Her abdominal exam was notable for distention, guarding, and rebound tenderness to palpation. A bedside ultrasound demonstrated large volume abdominal free fluid. She was taken to the operating room for exploratory laparotomy due to concern for intraabdominal hemorrhage.

Exploration of the abdominal cavity revealed large volume ascites, edematous bowel, and normal-appearing appendix and adnexa. The uterus was small, firm, and normal in appear-

ance. Her laboratory analysis resulted intraoperatively and was notable for hemoglobin 19.8 g/dL, WBC 135.1 10³/μL, sodium 129 mmol/L, creatinine 2.25 mg/dL, and lactate 8.5 mmol/L. Blood cultures and an endometrial biopsy for culture were sent when the elevated WBC count resulted, and vancomycin, piperacillin-tazobactam, and clindamycin were started. The patient's clinical status deteriorated further and a hysterectomy was performed for source control. During the hysterectomy, the patient experienced cardiac arrest that did not respond to resuscitation, and she expired on the operating table. The blood cultures never grew an organism, but the endometrial culture revealed *Clostridium sordellii*. Final uterine pathology demonstrated extensive necrosis of the endometrial lining extending to myometrium with acute inflammation and hemorrhagic necrosis of the bilateral adnexa. Autopsy findings were consistent with death due to toxic shock.

DISCUSSION

Clostridia are anaerobic, spore-forming, gram-positive rods that are a commensal in the vaginal secretions of 5% to 20% of asymptomatic people and are a rare cause of obstetric and gynecologic infections.^{2,9-16} In this report, we present 2 cases of uterine clostridial myonecrosis (gas gangrene), a rare and deadly manifestation of clostridial infection with mortality rates between 50% and 100%.^{9,10} In cases of clostridial myonecrosis, *C perfringens* is most commonly isolated (found in 80% of cases), followed by *C novyi* and *C septicum*. Other more rare clostridial species causing myonecrosis include *C histolyticum*, *C sordellii*, and *C fallax*.^{13,15,17}

Most fatal cases of postpartum infection have involved one of these Clostridial species or other toxin-producing bacteria, such as Group A Strep.⁴

Pathogenesis

Clostridial uterine myonecrosis occurs when clostridial organisms within the normal intestinal or vaginal flora spread into new spaces through a breach in anatomical defense barriers.¹⁰ Severity of infection results from bacterial production of toxins.¹³

C septicum

The bacterium encountered in the first case is *C septicum*, an organism commonly identified in gas gangrene, but a rare cause of obstetric and gynecologic infection. We identified 7 other cases in the literature – 3 with gynecologic malignancy and 4 peripartum patients.^{12,18–23} *C septicum* is an aerotolerant organism 300 times more virulent than *C perfringens*.^{15,21} The virulence of *C septicum* stems from its 4 toxins, the most lethal of which is the alpha toxin, which produces lecithinase—a phospholipase that causes ischemic tissue necrosis and hemolysis. The creation of devitalized tissue by toxin-generated ischemia produces an anaerobic environment that results in rapid disease spread. Antibiotics cannot penetrate this devitalized tissue, making rapid source control via surgical debridement imperative.

C sordellii

C sordellii is an uncommon and transient isolate of vaginal and rectal flora, found in 3.4% of asymptomatic reproductive-aged women in the United States.²⁴ Uterine myonecrosis from *C sordellii* constitutes a rapidly progressing and nearly always fatal infection. Though rare, it is a known complication of medication abortion and also has been seen in peripartum infections and after gynecologic surgery.^{25–29} Similar to *C septicum*, virulence results from the production of 7 known toxins, of which the hemorrhagic and lethal toxins are considered primarily responsible for pathogenic infection.

Diagnosis

While clinical manifestations of *C sordellii* and *C septicum* share some features, each presents differently (Table). Both infections are associated with tachycardia and pain out of proportion to examination findings. Patients with *C septicum* typically have fever, sometimes hemorrhagic bullae or soft tissue crepitations and – once shock develops – hypotension, multiple organ failure, and disseminated intravascular coagulation.²¹ Patients with *C sordellii* infection are typically afebrile but have refractory hypotension, tachycardia, and a profound capillary leak syndrome causing large volume ascites.^{25,27}

Laboratory findings are similar in both infections and early on are remarkable for hyponatremia and marked leukocytosis. Hyponatremia is caused by both sepsis physiology and the extensive third spacing of fluids seen in necrotizing soft tissue infections. Serum sodium levels less than 135 mEq/L and WBC

count of greater 15.4 10³/μL are useful thresholds to distinguish necrotizing soft tissue infections from non-necrotizing infections.^{24,25,30} Leukocytosis, while present in both clostridial infections, is markedly elevated (50–200 10³/μL) in cases of *C sordellii*.^{25,27,31} Later laboratory findings for both infections include elevated lactate and creatine kinase levels, as well as signs of multisystem organ failure such as elevated creatinine and liver function tests. *C septicum* often causes coagulopathy—including thrombocytopenia, fibrinogenemia, anemia, and elevated INR – where hemoconcentration is seen with *C sordellii*. Blood and all tissue specimens suspected to be infected should be sent for Gram stain and culture. Gram stain will show gram-positive or gram-variable rods and often a paucity of neutrophils, thought due to toxin-mediated destruction of these cells.¹⁵ Culture is less useful in the initial diagnostic phase as clostridial species can take several days to speciate.

Imaging—typically computed tomography—may demonstrate myometrial gas, which can expedite confirmation of a diagnosis. In our first case, we saw diffuse echogenic foci with “dirty posterior shadowing” on bedside ultrasound of the uterus. In retrospect, this finding was likely due to the presence of extensive gas in the myometrium; similar ultrasonographic descriptions of intramuscular gas exist in the literature in cases of emphysematous cholecystitis.³⁰ Our review of the literature revealed no other reports of utilizing point-of-care ultrasound to evaluate for the presence of myometrial gas. We propose this as another diagnostic tool to aid in more rapid diagnosis of uterine myonecrosis.

Treatment

The principles of treatment for clostridial myonecrosis are the same regardless of causative species: broad-spectrum antibiotics; early, aggressive surgical debridement of infected tissues; and expeditious cardiovascular and blood product support. Clostridial species are nearly universally susceptible to penicillin-based antibiotics. Clindamycin is recommended due to its inhibition of bacterial protein synthesis and mitigating effects of circulating clostridial toxins; however, an improved clinical benefit has not been documented.^{32,33} While antibiotic therapy is necessary, the rapidly expanding volume of devitalized tissue in clostridial necrotizing infections means antibiotic penetrance is minimal. Early surgical exploration and aggressive resection of all necrotic tissue is required to gain source control and allow for increased antibiotic efficacy.

CONCLUSIONS

Though rare, uterine clostridial myonecrosis can have tragic consequences, as demonstrated by these cases. Early recognition of the clinical features associated with clostridium infections—pain out of proportion to exam, tachycardia, leukocytosis, hyponatremia, and myometrial gas on imaging—may allow for prompt diagnosis and life-saving treatment. Most clostrid-

ium infections occur in patients of child-bearing age, rendering the decision to perform hysterectomy difficult. However, swift surgical action for effective infection source control is imperative for patient survival. Clinicians must utilize a high index of suspicion to promptly diagnose and treat these rare but devastating infections.

Funding/Support: This research did not receive any specific grant from funding agencies in the public, commercial, or not-for-profit sectors. Elise Cowley is a Medical Science Training Program student and was supported by a National Library of Medicine training grant to the Computation and Informatics in Biology and Medicine Training Program (NLM 5T15LM007359) at UW-Madison and in part by MSTP grant T32GM140935.

Financial Disclosures: None declared.

Acknowledgements: The authors thank Amanda Wildenberg and Cassidy Slinger for administrative support and Michael Fritsch, MD, Department of Pathology, UW-Madison, for the photos provided as figures

REFERENCES

1. Gibbs RS, Duff P. Progress in pathogenesis and management of clinical intraamniotic infection. *Am J Obstet Gynecol*. 1991;164(5 Pt 1):1317-1326. doi:10.1016/0002-9378(91)90707-x
2. Al-Ostad G, Kezouh A, Spence AR, Abenham HA. Incidence and risk factors of sepsis mortality in labor, delivery and after birth: population-based study in the USA. *J Obstet Gynaecol Res*. 2015;41(8):1201-1206. doi:10.1111/jog.12710
3. Edwards SE, Grobman WA, Lappen JR, et al. Modified obstetric early warning scoring systems (MOEWS): validating the diagnostic performance for severe sepsis in women with chorioamnionitis. *Am Obstet Gynecol*. 2015;212(4):536.e1-536.e8. doi:10.1016/j.ajog.2014.11.007
4. Dempsey A. Serious infection associated with induced abortion in the United States. *Clin Obstet and Gynecol*. 2012;55(4):888-892. doi:10.1097/GRF.0b013e31826fd8f8
5. Romero R, Miranda J, Kusanovic JP, et al. Clinical chorioamnionitis at term I: microbiology of the amniotic cavity using cultivation and molecular techniques. *J Perinat Med*. 2015;43(1):19-36. doi:10.1515/jpm-2014-0249
6. Tanaka H, Katsuragi S, Hasegawa J, et al. The most common causative bacteria in maternal sepsis-related deaths in Japan were group A Streptococcus: a nationwide survey. *J Infect Chemother*. 2019;25(1):41-44. doi:10.1016/j.jiac.2018.10.004
7. van Dillen J, Zwart J, Schutte J, van Roosmalen J. Maternal sepsis: epidemiology, etiology and outcome. *Curr Opin in Infect Dis*. 2010;23(3):249-254. doi:10.1097/QCO.0b013e3182339257c
8. Carapetis JR, Steer AC, Mulholland EK, Weber M. The global burden of group A streptococcal diseases. *Lancet Infect Dis*. 2005;5(11):685-694. doi:10.1016/S1473-3099(05)70267-X
9. Eschenbach DA. Vaginal infection. *Clin Obstet Gynecol*. 1983;26(1):186-202. doi:10.1097/00003081-198303000-00023
10. Decker WH, Hall W. Treatment of abortions infected with clostridium welchii. *Am J Obstet Gynecol*. 1966;95(3):394-399. doi:10.1016/0002-9378(66)90124-4
11. Kurashina R, Shimada H, Matsushima T, Doi D, Asakura H, Takeshita T. Spontaneous uterine perforation due to clostridial gas gangrene associated with endometrial carcinoma. *J Nippon Med Sch*. 2010;77(3):166-169. doi:10.1272/jnms.77.166
12. Moore DH, Ghosh K, Sutton GP. Spontaneous occurrence of gangrene due to clostridium septicum in a patient with advanced endometrial carcinoma. *Infect Dis Obstet Gynecol*. 1994;2(1):34-37. doi:10.1155/S1064744994000372
13. Halpin TF, Molinari JA. Diagnosis and management of clostridium perfringens sepsis and uterine gas gangrene. *Obstet Gynecol Surv*. 2002;57(1):53-57. doi:10.1097/00006254-200201000-00024
14. Kocarev M, Girn Z, Collyer TC, Swindells S. Uterine clostridial myonecrosis after thermal balloon endometrial ablation. *Obstet Gynecol*. 2012;120(2 Pt 2):483-485. doi:10.1097/AOG.0b013e31825a725d
15. Cohen-Paradosu R, Kasper DL. Anaerobic infections: general concepts. In: Bennett JE, Dolin R, Blaser MJ, eds. *Mandell, Douglas, and Bennett's Principles and Practice of Infectious Diseases*. 9th ed. Elsevier; 2020:2923-2932.
16. Onderdonk AB, Garrett W. Diseases caused by *Clostridium*. In: Bennett JE, Dolin R, Blaser MJ, eds. *Mandell, Douglas, and Bennett's Principles and Practice of Infectious Diseases*. 9th ed. Elsevier; 2960-2968.
17. Present DA, Meislin R, Shaffer B. Gas gangrene. A review. *Orthop Rev*. 1990;19(4):333-341.
18. Haas LEM, Tjan DHT, van Zanten ARH. Fatal *Clostridium septicum* infection in a young pregnant woman. *Neth J Med*. 2006;64(7):254-255.
19. Khoo CL, Meskhi A, Harris CP. Fatal *Clostridium septicum* following medical termination of pregnancy. *J Obstet Gynaecol*. 2013;33(5):530-530. doi:10.3109/01443615.2013.788138
20. McDonald RE, Moola S. *Clostridium septicum* infection in a young pregnant patient. *BMJ Case Rep*. 2012;2012:bcr2012006254. doi:10.1136/bcr-2012-006254
21. Prinszen HM, Hoekman K, Burger CW. *Clostridium septicum* myonecrosis and ovarian cancer: a case report and review of literature. *Gynecol Oncol*. 1999;72(1):116-119. doi:10.1006/gyno.1998.5209
22. Zurmeyer S, Fotopoulou C, Braicu E, Schlichting U, Sehouli J. *Clostridium septicum* can cause distant myonecrosis in patients with ovarian cancer. *Anticancer Res*. 2013;33(4):1585-1589.
23. Rimawi BH, Graybill W, Pierce JY, et al. Necrotizing fasciitis and toxic shock syndrome from clostridium septicum following a term cesarean delivery. *Case Rep Obstet Gynecol*. 2014;2014:1-5. doi:10.1155/2014/724302
24. Chong E, Winikoff B, Charles D, et al. Vaginal and rectal clostridium sordellii and clostridium perfringens presence among women in the United States. *Obstet Gynecol*. 2016;127(2):360-368. doi:10.1097/AOG.0000000000001239
25. Aldape MJ, Bayer CR, Bryant AE, Stevens DL. A novel murine model of *Clostridium sordellii* myonecrosis: insights into the pathogenesis of disease. *Anaerobe*. 2016;38:103-110. doi:10.1016/j.anaerobe.2016.01.004
26. Centers for Disease Control and Prevention (CDC). *Clostridium sordellii* toxic shock syndrome after medical abortion with mifepristone and intravaginal misoprostol—United States and Canada, 2001-2005. *MMWR Morb Mortal Wkly Rep*. 2005;54(29):724..
27. Fischer M, Bhatnagar J, Guarner J, et al. Fatal toxic shock syndrome associated with *clostridium sordellii* after medical abortion. *N Engl J Med*. 2005;353(22):2352-2360. doi:10.1056/NEJMoa051620
28. Soper DE. Abortion and clostridial toxic shock syndrome. *Obstet Gynecol*. 2007;110(5):970-971. doi:10.1097/01.AOG.0000288224.47104.7b
29. Fjerstad M, Trussell J, Sivin I, Lichtenberg ES, Cullins V. Rates of serious infection after changes in regimens for medical abortion. *N Engl J Med*. 2009;361(2):145-151. doi:10.1056/NEJMoa0809146
30. Ballard DH, Mazaheri P, Raptis CA, et al. Fournier gangrene in men and women: appearance on CT, ultrasound, and MRI and what the surgeon wants to know. *Can Assoc Radiol J*. 2020;71(1):30-39. doi:10.1177/0846537119888396
31. Aldape MJ, Bryant AE, Stevens DL. *Clostridium sordellii* infection: epidemiology, clinical findings, and current perspectives on diagnosis and treatment. *Clin Infect Dis*. 2006;43(11):1436-1446. doi:10.1086/508866
32. Stevens DL, Bryant AE, Hackett SP. Antibiotic effects on bacterial viability, toxin production, and host response. *Clin Infect Dis*. 1995;20 Suppl 2:S154-157. doi:10.1093/clindis/20.supplement_2.s154
33. Hamada S, Nakajima M, Kaszynski RH, et al. Association between adjunct clindamycin and in-hospital mortality in patients with necrotizing soft tissue infection due to group A streptococcus: a nationwide cohort study. *Eur J Clin Microbiol Infect Dis*. 2022;41(2):263-270. doi:10.1007/s10096-021-04376-2