

Orofacial Actinomycosis Eroding Through Hard Palate: A Case Report

Stephanie Liu, MD; Charissa M. Etrheim, MD; Kevin M. McDonald, MD

ABSTRACT

Introduction: Actinomycosis is a rare, chronic, progressive bacterial infection caused by *Actinomyces* species with a reported incidence of 1 in 300 000. Actinomycosis has variable presentations and is commonly mistaken for malignancy and other infections, leading to delays in diagnosis and appropriate treatment. *Actinomyces* is a commensal bacteria found in the mouth, gut, and genitourinary tract. Actinomycosis tends to take advantage of anatomical defects for contiguous spread and can cause fistulas, sinus tracts, abscesses, and intrauterine device-associated infections.

Case Presentation: A 78-year-old White male with known dental caries came to a primary care clinic 2 days after noticing a painless, nonbleeding mass eroding from his hard palate. After a tissue biopsy of the mass showed a diagnosis of actinomycosis and advanced imaging showed no intracranial involvement, he was treated with a 6-month course of antibiotics, including oral amoxicillin, oral amoxicillin-clavulanate, and intravenous ertapenem.

Discussion: There are several case reports of actinomycosis with variable presentations, such as cutaneous nodules and sinus tracts. These cases frequently are associated with dental infections and procedures, trauma, oral surgery, or prior head and neck radiation. The condition is often mistaken for other infections or malignancy, which can delay appropriate treatment and increase the risk of complications.

Conclusions: Actinomycosis is a rare bacterial infection with variable presentations occurring throughout the body. This patient responded well to a prolonged course of intravenous and oral antibiotics and had complete healing of his hard palate defect. Actinomycosis is frequently misdiagnosed, leading to delays in appropriate treatment.

• • •

Author Affiliations: Department of Family Medicine and Community Health, University of Wisconsin School of Medicine and Public Health (UWSMPH), Madison, Wisconsin (Liu, Etrheim); Department of Radiology, UWSMPH, Madison, Wisconsin (McDonald).

Corresponding Author: Stephanie Liu, MD, email sliu735@wisc.edu.

INTRODUCTION

Actinomycosis is a rare, chronic, progressive bacterial infection with a reported incidence of 1 in 300 000.¹ It is caused by *Actinomyces*, a commensal bacteria found in the mouth, gut, and genitourinary tract. Actinomycosis has variable presentations and is commonly mistaken for malignancy and other infections, leading to delays in diagnosis and appropriate treatment. It tends to take advantage of anatomical defects for contiguous spread and can cause fistulas, sinus tracts, abscesses, and IUD-associated infections.

In this report, we present the case of patient who presented with orofacial actinomycosis eroding through his hard palate.

CASE PRESENTATION

A 78-year-old White male with a history of hypertension presented to the primary care clinic with concerns of a painless mass eroding from his hard palate. He had no known allergies and was not taking any medications on a regular basis. He first noticed a dangling piece of tissue emerging from a hole in his right hard palate about 2 days earlier. He had no recent dental procedures and denied any significant trauma or injuries to the oral cavity. He reported otherwise feeling well, except for mild decreased energy and appetite over the previous month. He was not experiencing any associated bleeding, drainage, pain, fevers, or difficulty swallowing. Of note, his dentist recently had recommended extraction of tooth no. 1, where he had been experiencing mild pain.

Additionally, the patient had been seen 1 week prior in the primary care clinic for dizziness, intermittent right-sided head-

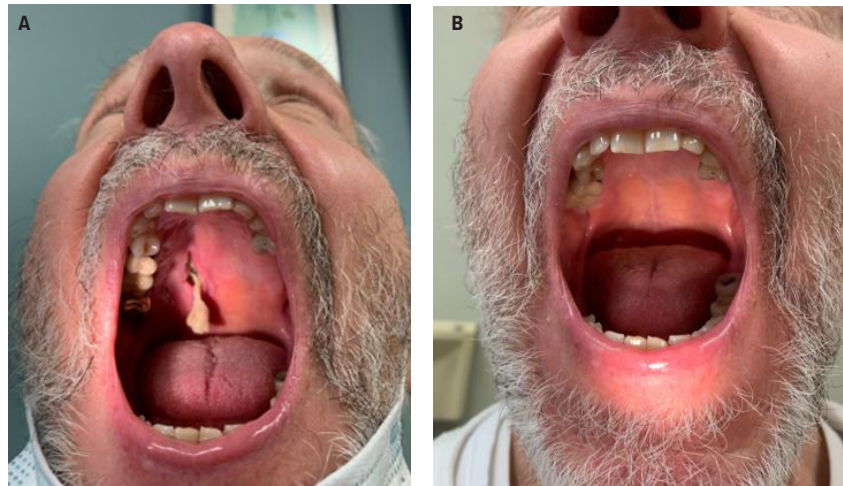aches, and subtle static facial asymmetry. At the time of the previous clinic visit for dizziness, his hard palate was not examined, and he was sent to the emergency department for a stroke workup that was negative, including fast brain magnetic resonance imaging (MRI) that did not show any acute abnormalities.

On examination, the patient appeared well overall. His vital signs were normal, including his temperature. His speech sounded normal, and his previous dizziness and facial drooping had improved. In his mouth, he had multiple cavities and a visible hole in the right side of the hard palate with a white, soft lesion emerging into the oral cavity (Figure 1A). The lesion and hard palate were not tender to touch. For diagnostic purposes, the lesion was truncated by excising the accessible portion with scissors. The hard palate defect was not probed to its depth. The eroding mass was sent for surgical pathology evaluation. The patient had no bleeding or discomfort when the lesion was cut, and he did not require local anesthesia. There was some initial concern for cancer given the cavitary nature of the lesion. The subsequent histopathology report returned with clumped colonies of *actinomyces sulfur granules*.

The patient was referred to the Infectious Disease clinic for further evaluation and management of his orofacial *actinomyces* infection. Computed tomographic (CT) maxillofacial imaging with contrast demonstrated asymmetric enlargement of the right greater palatine foramen with a defect in the right palatine and with abnormal soft tissue attenuation in the right pterygopalatine fossa. An MRI brain with and without contrast was then performed to rule out intracranial involvement. This demonstrated an ulcerative lesion of the right hard palate and contiguous inflammatory changes in the right maxillary alveolus, right greater palatine canal, and right pterygopalatine fossa without extension into the orbit, central skull base, or brain parenchyma (Figure 2). He also was evaluated by an ear, nose, and throat (ENT) specialist for possible surgical intervention. The ENT specialist performed a punch biopsy at the base of the cavitary lesion to rule out malignancy. This biopsy was benign and showed squamous mucosa with evidence of inflammation. After reviewing the images, the ENT specialist indicated that surgical intervention was not needed.

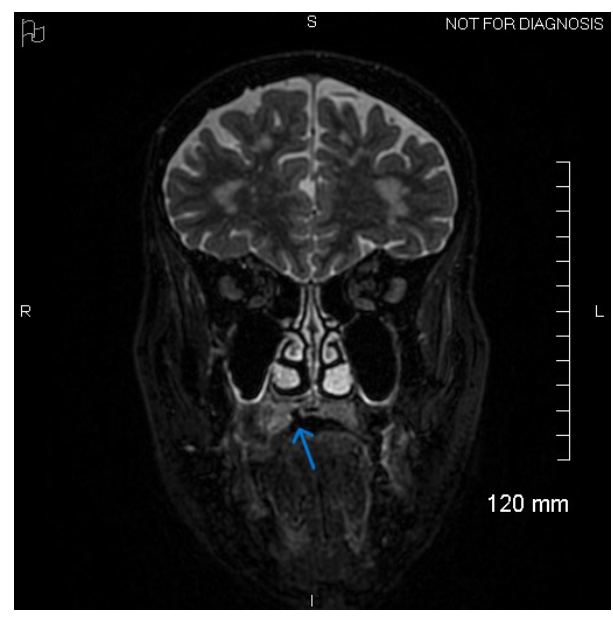
Per Infectious Disease recommendations, the patient was initiated on amoxicillin 500 mg and amoxicillin-clavulanate 875/125 mg every 8 hours, which served as a bridging therapy for 3 days until treatment with intravenous (IV) ertapenem was able to be coordinated in the outpatient setting. He completed

Figure 1. Photos of Patient's Oral Cavity



1A. Photo demonstrating mass eroding through the right hard palate, taken prior to biopsy.
1B. Photo demonstrating resolution of hard palate defect at 6-month follow-up.

Figure 2. Coronal Magnetic Resonance Imaging.



Arrow pointing to hard palate defect.

3 weeks of IV ertapenem, 1 gram every 24 hours, and was then transitioned to a regimen of amoxicillin-clavulanate acid and amoxicillin for an additional 4 weeks. On repeat evaluation after 7 weeks of antimicrobial therapy, the defect in the hard palate had healed, and he was transitioned to single agent amoxicillin 1 g every 8 hours to complete a total of 6 months of treatment. During his treatment course, he had dental extraction of tooth no. 1, which had been causing pain and was thought to be the inciting factor for the *actinomyces* infection.

At his 6-month follow-up visit, the patient had complete heal-

Table. Characteristics of Seven Case Reports Describing Actinomycosis

Author/Date	Age	Symptoms	Location	Treatment
Mehta et al ⁸ (2007)	11 y	Otorrhea, otalgia, facial weakness	Temporal bone involving facial nerve	Debridement, 9 weeks of ampicillin/sulbactam
Bose et al ¹⁰ (2014)	32 y	Painless nodules, draining sinuses	Back and axilla	Penicillin and TMP-SMX followed by amoxicillin and TMP-SMX (unspecified duration)
Almarzouq et al ¹¹ (2019)	35 y	Painless mass	Great toe	Local excision, 6 weeks of clindamycin
Han et al ¹² (2020)	54 y	Lower abdominal pain, anorexia, vomiting	Pelvic cavity	2 weeks of penicillin
Sah et al ¹³ (2020)	35 y	Headache, weakness, vomiting	Brain	Excision, ampicillin-sulbactam followed by oral antibiotics (unspecified duration)
Mou et al ⁷ (2021)	5 y	Fevers, pain, erythema, sores	Popliteal fossa	Debridement, 7 weeks of ampicillin-sulbactam followed by 6 weeks of oral amoxicillin-clavulanate
Yuan et al ¹⁴ (2022)	47 y	Productive cough, dyspnea, fever	Lung	10 days of piperacillin-sulbactam and 7 months of amoxicillin-clavulanate

Abbreviations: y, years; TMP-SMX, trimethoprim-sulfamethoxazole.

ing of the defect in the right hard palate (Figure 1B). Infectious Disease recommended that he have a follow-up MRI to confirm eradication of the deep infection; however, he said he was feeling well and declined the MRI. Since he had demonstrated an initial rapid response to antibiotic therapy with complete healing of the hard palate, he was discharged from Infectious Disease care with guidance on monitoring for relapse of symptoms.

DISCUSSION

Actinomyces are nonmotile, filamentous, gram-positive, non-acid fast, and obligate anaerobic bacteria found as a commensal organism of the oropharynx, gastrointestinal tract, genitourinary tract, and skin.² Actinomycosis is a rare, progressive, chronic granulomatous disease that can occur in cervicofacial, thoracic, abdominopelvic, cerebral, and other forms.²⁻⁴ *Actinomyces israelii* is the most encountered species, but many different species have been described to cause infections in various anatomical sites.⁵ Peak incidence occurs in the fourth to fifth decade of life, with males more commonly affected than females in a 3:1 ratio.⁶ Risk factors for actinomycosis include dental caries, infections of erupting teeth, gingivitis, dental extractions, the presence of intrauterine and intravaginal devices, diabetes, alcohol use disorder, malnutrition, and malignancy.⁷

Actinomycosis can spread directly into adjacent tissue by taking advantage of defects in anatomic barriers to form abscesses, sinus tracts, necrosis, fibrosis, and fistulae. Actinomycosis lesions are often painless, as in this patient's case, but they have been described to cause pain.⁸ This patient had been seen a week prior to evaluation of the mass for complaints of dizziness and headache. Actinomycosis was thought to be a possible explanation for these symptoms. There has been at least 1 other case report describing facial nerve palsy from actinomycosis.⁹ Actinomycosis presents in a variety of forms and can easily mimic other infections and neoplasms, leading to misdiagnosis or delay in diagnosis. Cervicofacial actinomycosis is the most

common clinical presentation and is often described as “lumpy jaw syndrome,” with a tendency to affect the upper and lower mandibles.^{7,10} The literature on actinomycosis is limited, but there are several case reports describing variable presentations (Table)^{8-9,11-15} This patient had a history of known dental caries that had been recommended for extraction, which was performed during his antibiotic regimen.

The most accurate method of diagnosis is made via isolation of *Actinomyces* species on cultures of clinical specimens. *Actinomyces* species are slow growing in nature, so cultures should be observed for up to 21 days to allow time for adequate detection. The presence of characteristic yellow “sulfur” granules on histopathology sections is strongly suggestive of *Actinomyces*, although granules are not seen consistently on all clinical specimens. Species-specific monoclonal antibody staining has been shown to improve identification of various *Actinomyces* species,⁴ which could be useful when this diagnosis is suspected. Recently, molecular techniques using 16s rRNA gene probes also have assisted greatly in the diagnosis of actinomycosis.¹⁶ In this patient's case, a diagnosis was able to be made with histopathology.

Actinomycosis is typically treated with high-dose penicillin G, with amoxicillin, amoxicillin-clavulanate, ampicillin-sulbactam, and doxycycline used as alternatives. Actinomycosis historically has been treated with prolonged antibiotic courses up to 1 year in duration, with shorter treatment courses of 1 to 4 weeks described in more recent reports.^{17,18} Of note, actinomycosis infections can respond temporarily to shorter courses of broad-spectrum antibiotics prescribed for presumed odontogenic bacterial infections. This can lead to repeated short courses of antibiotics, promoting chronicity and formation of woody induration and fibrosis that can mimic malignancy. Increased clinician awareness of this condition can help prevent misdiagnosis and treatment delays.

This patient was treated with oral amoxicillin, amoxicillin-clavulanate, and IV ertapenem per Infectious Disease recommen-

datations. While IV penicillin is typically the agent of choice for actinomycosis, ertapenem was chosen over penicillin due to the invasive and erosive nature of this patient's actinomycosis infection.

CONCLUSIONS

This case report discusses a patient with a white mass eroding from his hard palate that was found to be a rare infection. The case adds to the limited literature describing various clinical presentations of actinomycosis affecting different organ systems and highlights how actinomycosis can invade through structures and mimic malignancy and other disease processes. Actinomycosis often is associated with dental infections and can take advantage of defects in anatomical barriers to spread and form abscesses, sinus tracts, and fistulas. Increased clinician awareness of the condition and appropriate methods of diagnosis can help prevent delays in treatment and complications from spreading infection.

Financial Disclosures: None declared.

Funding/Support: None declared.

Acknowledgements: The authors wish to thank their Infectious Disease and Ear, Nose, and Throat colleagues for their assistance in this patient's care. The patient described in this report provided written signed consent to use his photos, radiographic images, age, and demographics for the creation of this case report.

REFERENCES

1. Boyanova L, Kolarov R, Mateva L, Markovska R, Mitov I. Actinomycosis: a frequently forgotten disease. *Future Microbiol*. 2015;10(4):613-628. doi:10.2217/fmb.14.130
2. Li J, Li Y, Zhou Y, Wang C, Wu B, Wan J. Actinomyces and alimentary tract diseases: a review of its biological functions and pathology. *Biomed Res Int*. 2018;2018:3820215. doi:10.1155/2018/3820215
3. Gajdács M, Urbán E, Terhes G. Microbiological and clinical aspects of cervicofacial actinomyces infections: an overview. *Dent J (Basel)*. 2019;7(3):85. doi:10.3390/dj7030085
4. Smego RA Jr, Foglia G. Actinomycosis. *Clin Infect Dis*. 1998;26(6):1255-1263. doi:10.1086/516337
5. Bonnefond S, Catroux M, Melenotte C, et al. Clinical features of actinomycosis: a retrospective, multicenter study of 28 cases of miscellaneous presentations. *Medicine (Baltimore)*. 2016;95(24):e3923. doi:10.1097/MD.0000000000003923
6. Bennhoff DF. Actinomycosis: diagnostic and therapeutic considerations and a review of 32 cases. *Laryngoscope*. 1984;94(9):1198-1217. doi:10.1288/00005537-198409000-00013
7. Sharma S, Hashmi MF, Valentino DJ III. Actinomycosis. In: *StatPearls*. StatPearls Publishing; 2023. Accessed November 20, 2023. <https://www.ncbi.nlm.nih.gov/books/NBK482151/>
8. Mou Y, Jiao Q, Wang Y, et al. Musculoskeletal actinomycosis in children: a case report. *BMC Infect Dis*. 2021;21(1):1220. doi:10.1186/s12879-021-06890-2
9. Mehta D, Statham M, Choo D. Actinomycosis of the temporal bone with labyrinthine and facial nerve involvement. *Laryngoscope*. 2007;117(11):1999-2001. doi:10.1097/MLG.0b013e318133a127
10. Valour F, Sénéchal A, Dupieux C, et al. Actinomycosis: etiology, clinical features, diagnosis, treatment, and management. *Infect Drug Resist*. 2014;7:183-197. doi:10.2147/IDR.S39601

11. Bose M, Ghosh R, Mukherjee K, Ghoshal L. Primary cutaneous actinomycosis: a case report. *J Clin Diagn Res*. 2014;8(7):YD03-YD5. doi:10.7860/JCDR/2014/8286.4591
12. Almarzouq SF, Almarghoub MA, Almeshal O. Primary actinomycosis of the big toe: a case report and literature review. *J Surg Case Rep*. 2019;2019(11):rjz292. doi:10.1093/jscr/rjz292
13. Han Y, Cao Y, Zhang Y, Niu L, Wang S, Sang C. A case report of pelvic actinomycosis and a literature review. *Am J Case Rep*. 2020;21:e922601. doi:10.12659/AJCR.922601
14. Sah R, Nepal G, Sah S, et al. A rare case of brain abscess caused by *Actinomyces meyeri*. *BMC Infect Dis*. 2020;20(1):378. doi:10.1186/s12879-020-05100-9
15. Yuan Y, Hou Z, Peng D, Xing Z, Wang J, Zhang S. Pulmonary Actinomyces graevenitzi infection: case report and review of the literature. *Front Med (Lausanne)*. 2022;9:916817. doi:10.3389/fmed.2022.916817
16. Kuyama K, Fukui K, Ochiai E, et al. Identification of the actinomycete 16S ribosomal RNA gene by polymerase chain reaction in oral inflammatory lesions. *Oral Surg Oral Med Oral Pathol Oral Radiol*. 2013;116(4):485-491. doi:10.1016/j.oooo.2013.06.027
17. Moghimi M, Salentijn E, Debets-Ossenkop Y, Karagozoglu KH, Forouzanfar T. Treatment of cervicofacial actinomycosis: a report of 19 cases and review of literature. *Med Oral Patol Oral Cir Bucal*. 2013;18(4):e627-e632. doi:10.4317/medoral.19124
18. Könönen E, Wade WG. Actinomyces and related organisms in human infections. *Clin Microbiol Rev*. 2015;28(2):419-442. doi:10.1128/CMR.00100-14